

PRINCIPLES OF ENDOSCOPIC MANAGEMENT OF NASAL AND SKULL BASE TUMORS: A New Frontier

Steven D. Schaefer, MD, FACS

Professor and Chair

Department of Otolaryngology

New York Eye and Ear Infirmary

New York Medical College



ENDOSCOPIC MANAGEMENT OF NASAL/SKULL BASE TUMORS

CONCEPTS IN TREATMENT

Prior Experience Of the Surgeon

External Approaches to Tumor Resection

Endoscopic Sinusitis Surgery

Extended Endoscopic Intranasal Surgery

Endoscopic Intranasal Tumor Surgery

Nasal/Skull Base Tumors Characteristic

Tumor Histology and Biology

Tumor Location and Adjacent Structures

Tumor Size


Prior Treatment and Vascularity

A Graduated Approach to Treatment & Repair

Lateral Nasal Wall, Septum

Pterygopalatine Fossa

Skull Base



ENDOSCOPIC MANAGEMENT OF NASAL/SKULL BASE TUMORS

Prior Experience Of the Surgeon – Developing a Skill Set

External Approaches to Tumor Resection

Maxillectomy, **Infratemporal Fossa, CF Resection**

Endoscopic Sinusitis Surgery

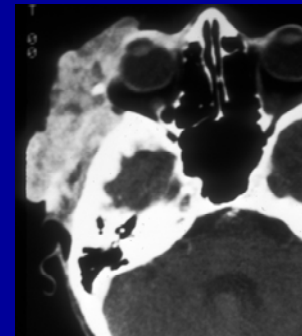
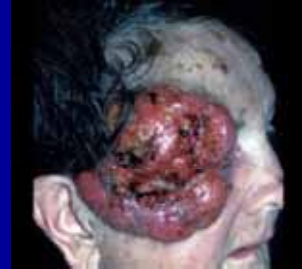Ethmoidectomy, Antrostomy, Sphenoidotomy,
Frontal Sinusotomy (types 1-2), Mucoceles

Extended Endoscopic Intranasal Surgery

Orbital/optic Nerve Decompression, CSF
Rhinorrhea and Dural Repair, DCR
Frontal Sinusotomy (type 3, Lothrop)

Endoscopic Intranasal Tumor Surgery

Resection Small Nasal Tumors
Medial Maxillectomy
Resection Large Nasal Tumors
Resection Pterygopalatine Fossa Tumors
Resection Skull Base and Pituitary/Clival Tumors



ENDOSCOPIC MANAGEMENT OF NASAL/SKULL BASE TUMORS

Prior Experience Of the Surgeon – Developing a Skill Set

External Approaches to Tumor Resection

Maxillectomy, Infratemporal Fossa, CF Resection

Endoscopic Sinusitis Surgery

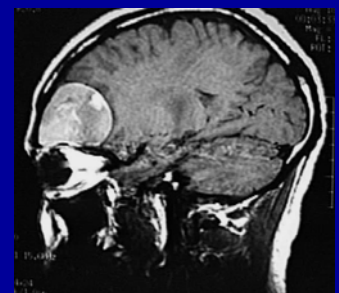
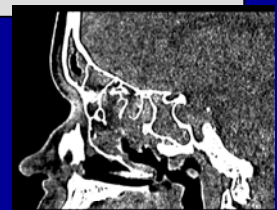Ethmoidectomy, Antrostomy, Sphenoidotomy,
Frontal Sinusotomy (types 1-2), Mucoceles

Extended Endoscopic Intranasal Surgery

Orbital/optic Nerve Decompression, CSF
Rhinorrhea and Dural Repair, DCR
Frontal Sinusotomy (type 3, Lothrop)

Endoscopic Intranasal Tumor Surgery

Resection Small Nasal Tumors
Medial Maxillectomy
Resection Large Nasal Tumors
Resection Pterygopalatine Fossa Tumors
Resection Skull Base and Pituitary/Clival Tumors



ENDOSCOPIC MANAGEMENT OF NASAL/SKULL BASE TUMORS

Prior Experience Of the Surgeon – Developing a Skill Set

External Approaches to Tumor Resection

Maxillectomy, Infratemporal Fossa, CF Resection

Endoscopic Sinusitis Surgery

Ethmoidectomy, Antrostomy, Sphenoidotomy,
Frontal Sinusotomy (types 1-2), Mucoceles

Extended Endoscopic Intranasal Surgery

Orbital/optic Nerve Decompression, CSF

Rhinorrhea and Dural Repair, DCR

Frontal Sinusotomy (type 3, Lothrop)

Endoscopic Intranasal Tumor Surgery

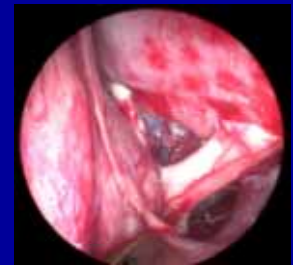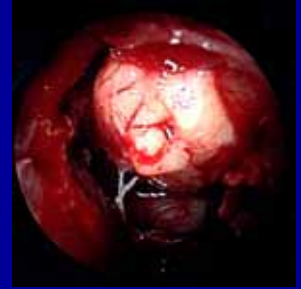
Resection Small Nasal Tumors

Medial Maxillectomy

Resection Large Nasal Tumors

Resection Pterygopalatine Fossa Tumors

Resection Skull Base and Pituitary/Clival Tumors



ENDOSCOPIC MANAGEMENT OF NASAL/SKULL BASE TUMORS

Nasal/Skull Base Tumors Imaging

Computed Tomography

- Best for bone – skull base, orbital wall, optic canal, bone remodeling

Magnetic Resonance Imaging

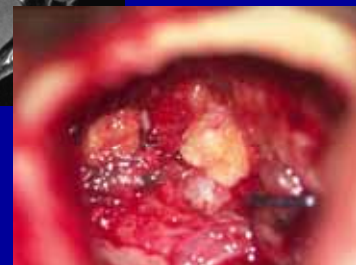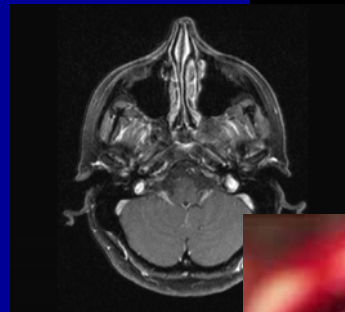
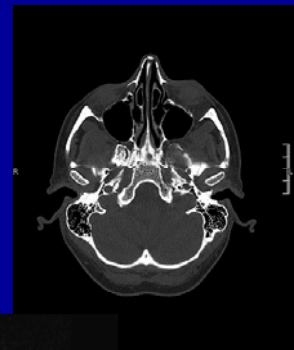
- Best for soft tissue – brain, dura, tumors, opacified sinus, orbit

PET/CT

- Best for evaluation of regional, metastatic and recurrent disease

Angiography

- Best for evaluation of blood supply, adjacent vascular structures and pre-op embolization



ENDOSCOPIC MANAGEMENT OF NASAL/SKULL BASE TUMORS

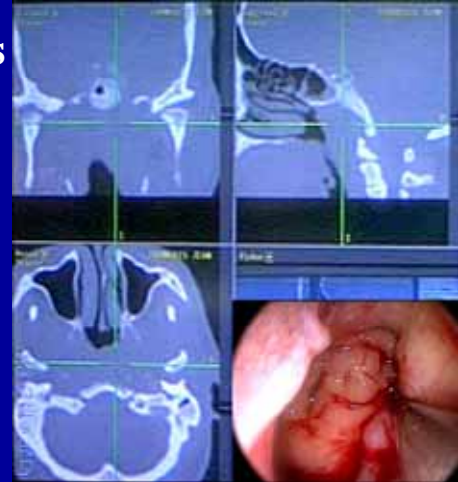
Nasal/Skull Base Tumors Imaging Computer Assisted Image Guidance and Staging

Computed Assisted Image Guided (CAIG) Surgery

- Best for – anterior and middle cranial fossa biopsy when site, borders or location questionable
wall, optic canal, bone remodeling

CAIG Staging Biopsy

- Best for - defining margins of tumor prior to resection



ENDOSCOPIC MANAGEMENT OF NASAL/SKULL BASE TUMORS

Nasal/Skull Base Tumors Characteristics

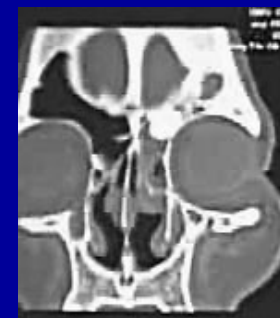Tumor Histology and Biology

Resectability – Benign > Malignant
Circumscribed > Invasive

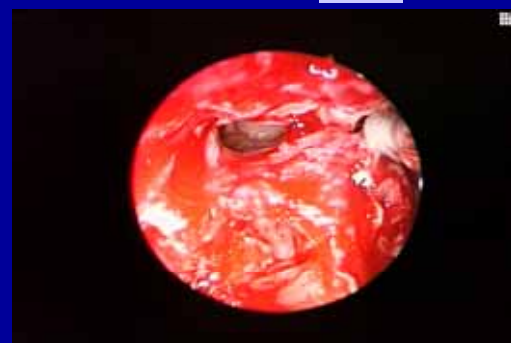
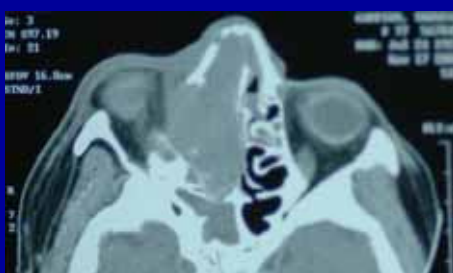
Tumor Location and Adjacent Structures

Tumor Size

Prior Treatment and Vascularity



Play



ENDOSCOPIC MANAGEMENT OF NASAL/SKULL BASE TUMORS

Nasal/Skull Base Tumors Characteristics

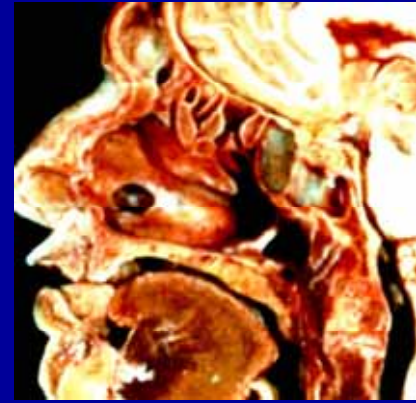
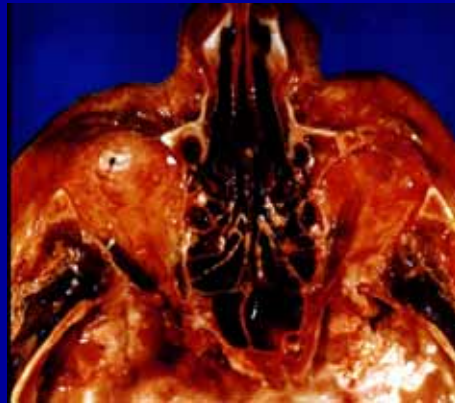Tumor Histology and Biology

Tumor Location and Adjacent Structures

Resectability – Nasal septum > lateral wall > extra-conal medial orbit > sphenoid sinus/ medial aspect optic nerve > pterygopalatine fossa > extradural cribriform plate & frontal bone > dura > intradural > brain

Tumor Size

Prior Treatment



ENDOSCOPIC MANAGEMENT OF NASAL/SKULL BASE TUMORS

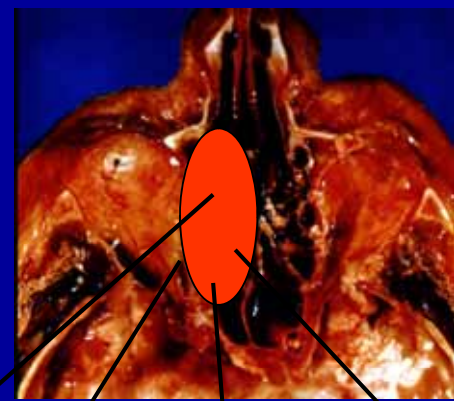
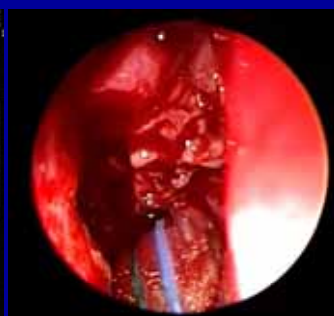
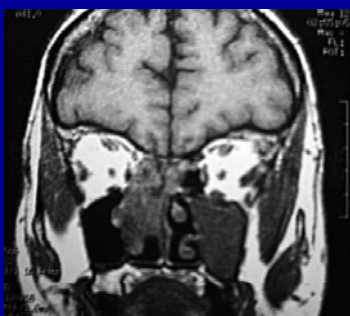
Nasal/Skull Base Tumors Characteristics

Tumor Histology and Biology

Tumor Location and Adjacent Structures

Tumor Size

Resectability – small and observable margins > large and ill-defined margins. **However -**
Prior Treatment and Vascularity



1

2

3

4

ENDOSCOPIC MANAGEMENT OF NASAL/SKULL BASE TUMORS

Nasal/Skull Base Tumors Characteristics

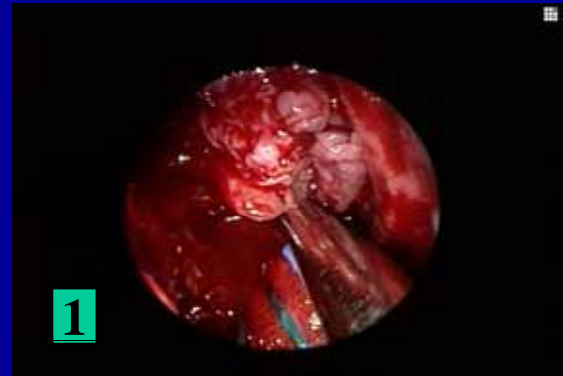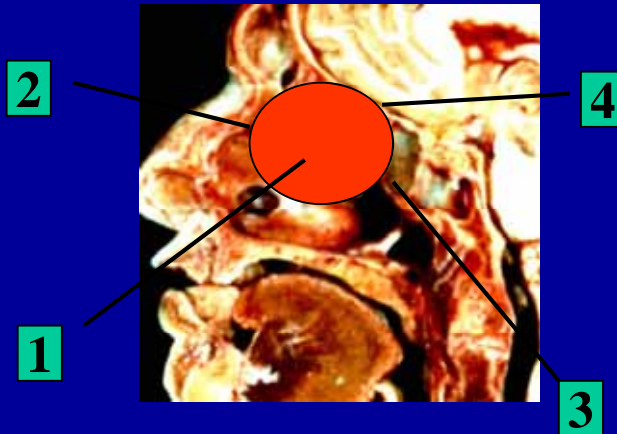
Tumor Histology and Biology

Tumor Location and Adjacent Structures

Tumor Size

Resectability – small and observable margins > large and ill defined margins. **However -**
Prior Treatment and Vascularity

[Play](#)



ENDOSCOPIC MANAGEMENT OF NASAL/SKULL BASE TUMORS

Nasal/Skull Base Tumors Characteristics

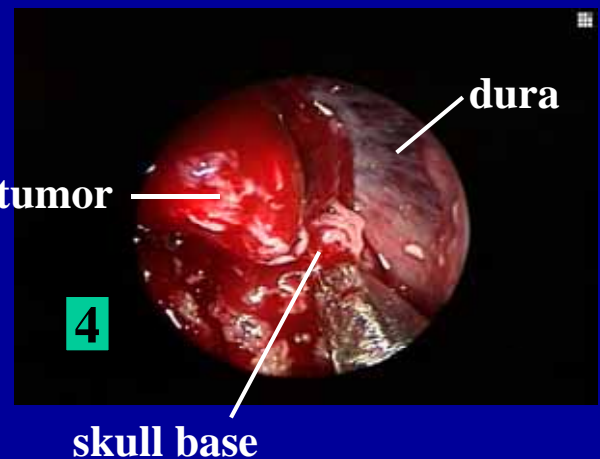
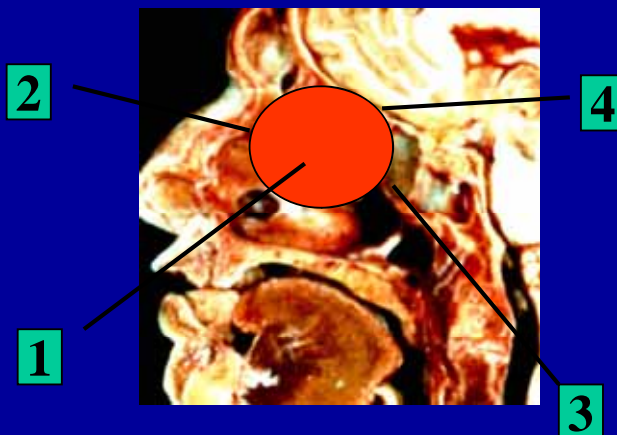
Tumor Histology and Biology

Tumor Location and Adjacent Structures

Tumor Size

Resectability – small and observable margins > large and ill defined margins. **However -**
Prior Treatment and Vascularity

[Play](#)



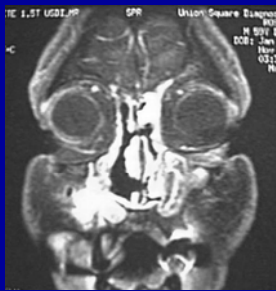ENDOSCOPIC MANAGEMENT OF NASAL/SKULL BASE TUMORS

A Graduated Approach to Treatment and Repair

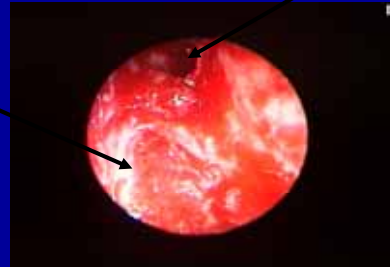
Lateral Nasal Wall, Septum
Pterygopalatine Fossa
Skull Base – Extradural ν Intradural

increasing complexity

frontal sinus

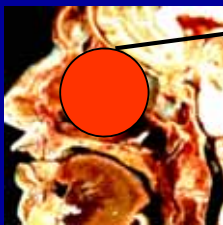


frontal bone

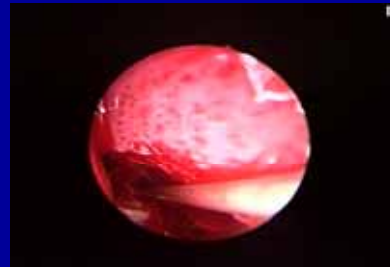


[Play](#)

4



4 resect
5 repair



[Play](#)

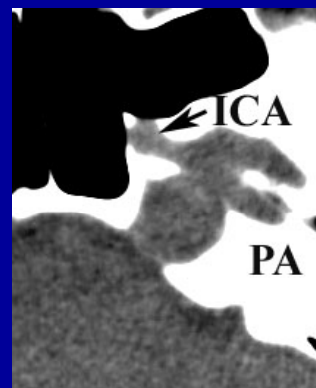
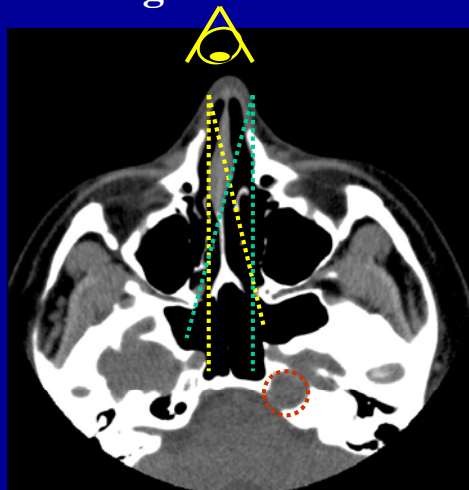
5

ENDOSCOPIC MANAGEMENT OF NASAL/SKULL BASE TUMORS

A Graduated Approach to Treatment and Repair

Lateral Nasal Wall, Septum
Pterygopalatine Fossa
Skull Base – Extradural ν Intradural
• Two Surgeons-Four Handed Technique

increasing complexity



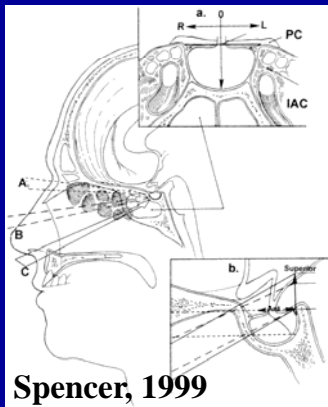
ENDOSCOPIC MANAGEMENT OF NASAL/SKULL BASE TUMORS

A Graduated Approach to Treatment and Repair

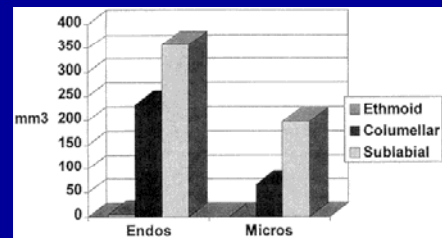
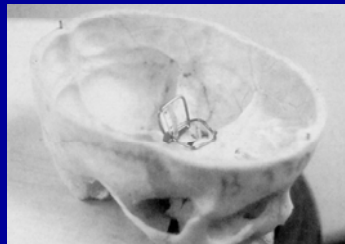Lateral Nasal Wall, Septum
Pterygopalatine Fossa
Skull Base – Extradural v Intradural

- Two Surgeons-Four Handed Technique
- Pituitary and Clival Surgery- selecting an approach

increasing complexity



Spencer, 1999



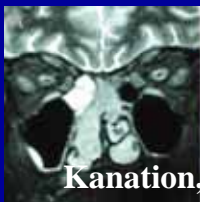ENDOSCOPIC MANAGEMENT OF NASAL/SKULL BASE TUMORS

A Graduated Approach to Treatment and Repair

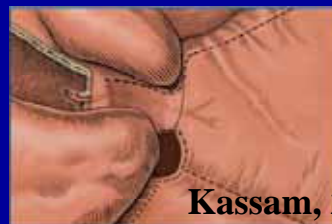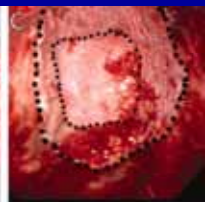
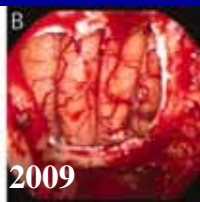Lateral Nasal Wall, Septum
Pterygopalatine Fossa
Skull Base – Extradural v Intradural

- Two Surgeons-Four Handed Technique
- Pituitary and Clival Surgery- reconstruction
- Anterior Skull Base - reconstruction

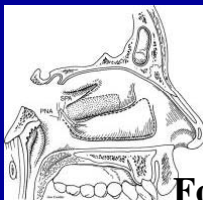
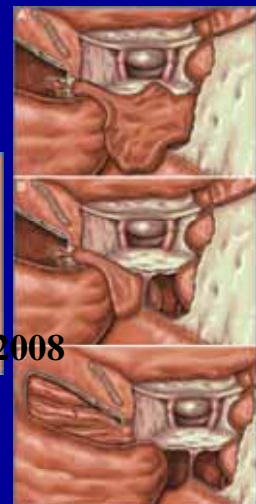increasing complexity



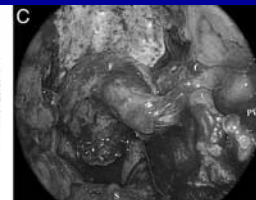
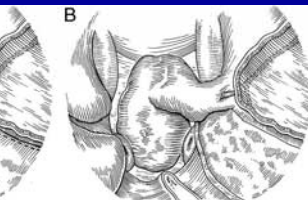
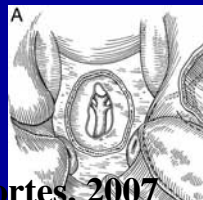Kanation, 2009



Kassam, 2008




Fortes, 2007



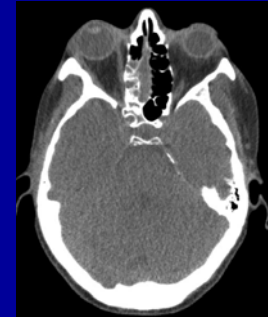
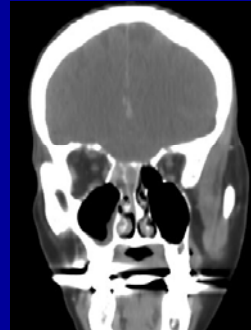ENDOSCOPIC MANAGEMENT OF NASAL/SKULL BASE TUMORS

Prior Experience Of the Surgeon – Developing a Skill Set And Surgical Judgment

External vs. Endoscopic Approaches



vs.



- 61 y/o female with right periorbital pain
- CT/MRI/PET-CT –tumor confined to ethmoid/skull base without dural invasion
- low grade adenoCA
- loss of smell

ENDOSCOPIC MANAGEMENT OF NASAL/SKULL BASE TUMORS

SUMMARY - CONCEPTS IN TREATMENT

Prior Experience Of the Surgeon

External Approaches to Tumor Resection

Endoscopic Sinusitis Surgery

Extended Endoscopic Intranasal Surgery

Endoscopic Intranasal Tumor Surgery

Nasal Tumors Characteristics

Tumor Histology and Biology

Tumor Location and Adjacent Structures

Tumor Size

Prior Treatment and Vascularity

A Graduated Approach to Treatment & Repair

Lateral Nasal Wall, Septum

Pterygopalatine Fossa

Skull Base (requires a surgical team)

