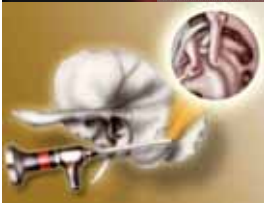

Butterfly Cartilage Tympanoplasty

David D Pothier

27th ALEXANDRIA INTERNATIONAL
COMBINED ORL CONGRESS

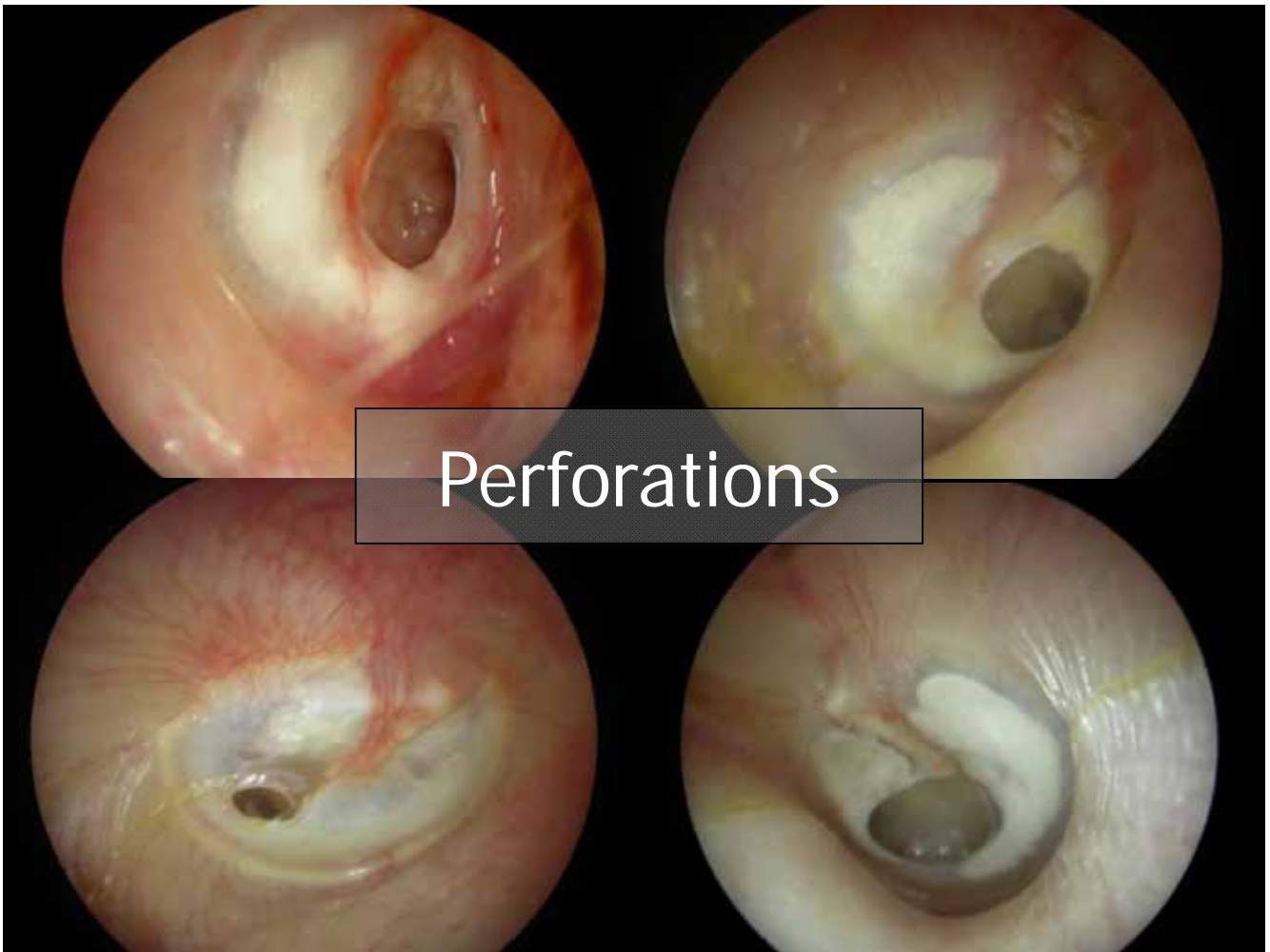
April 2009



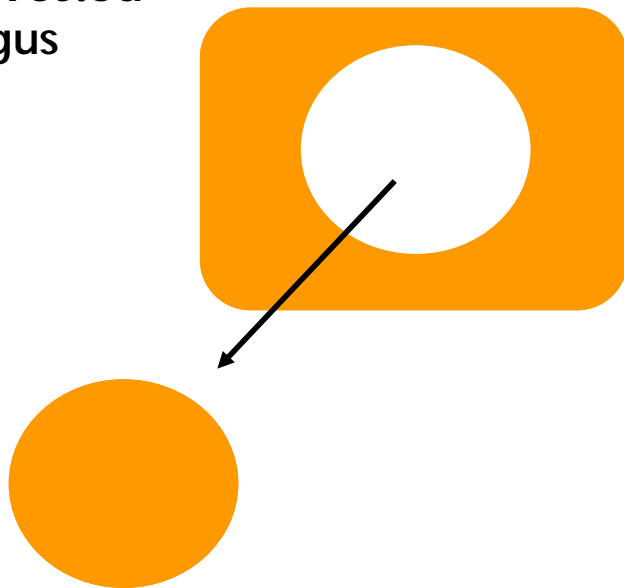
North Bristol NHS Trust **NHS**

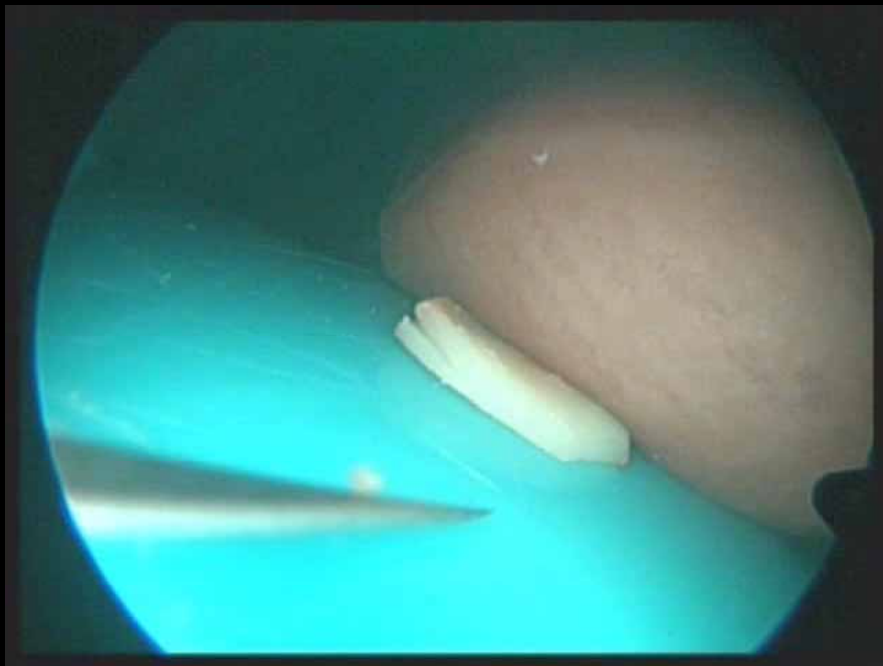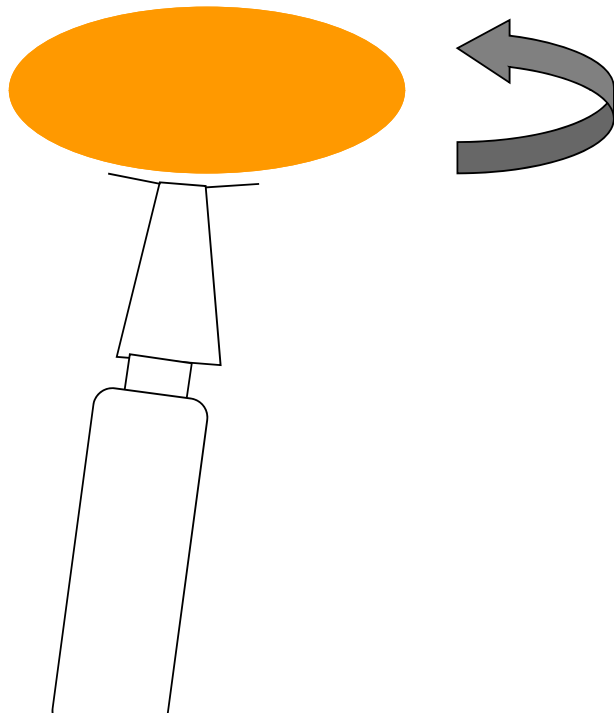
Butterfly myringoplasty

- Less invasive
- Favours otoendosurgery
- No flap raised
- Tiny skin incision



Harvested
tragus

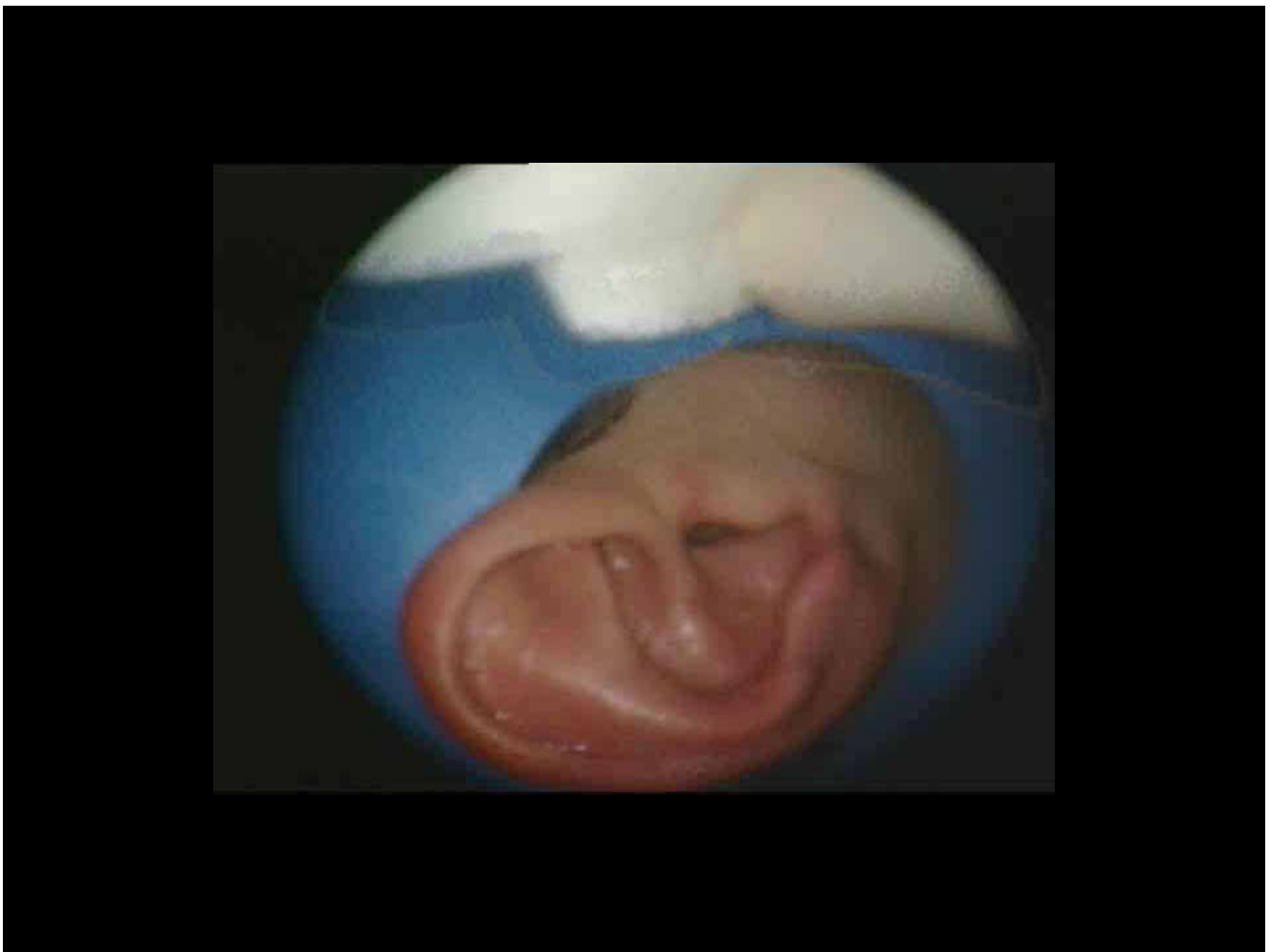
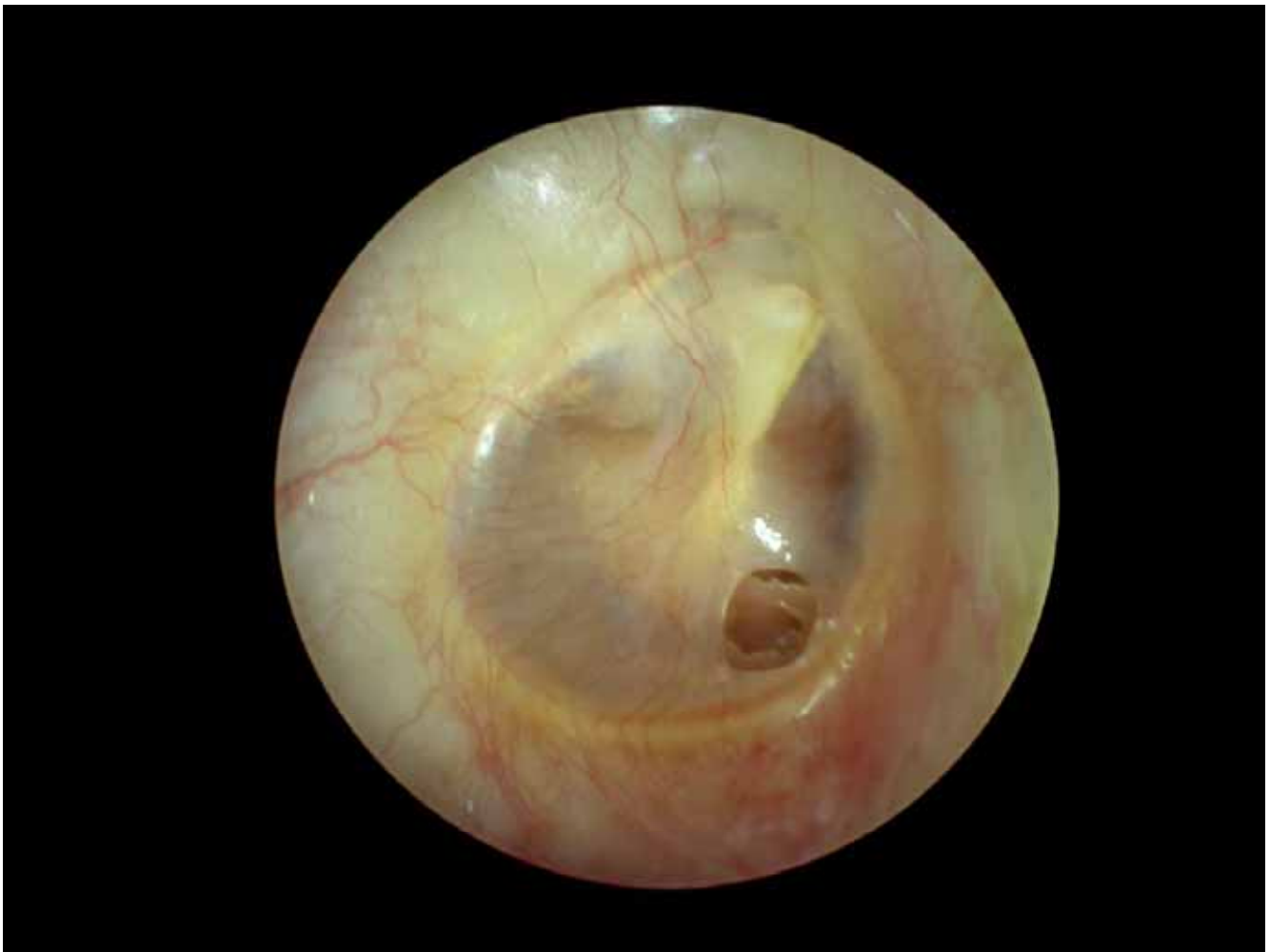




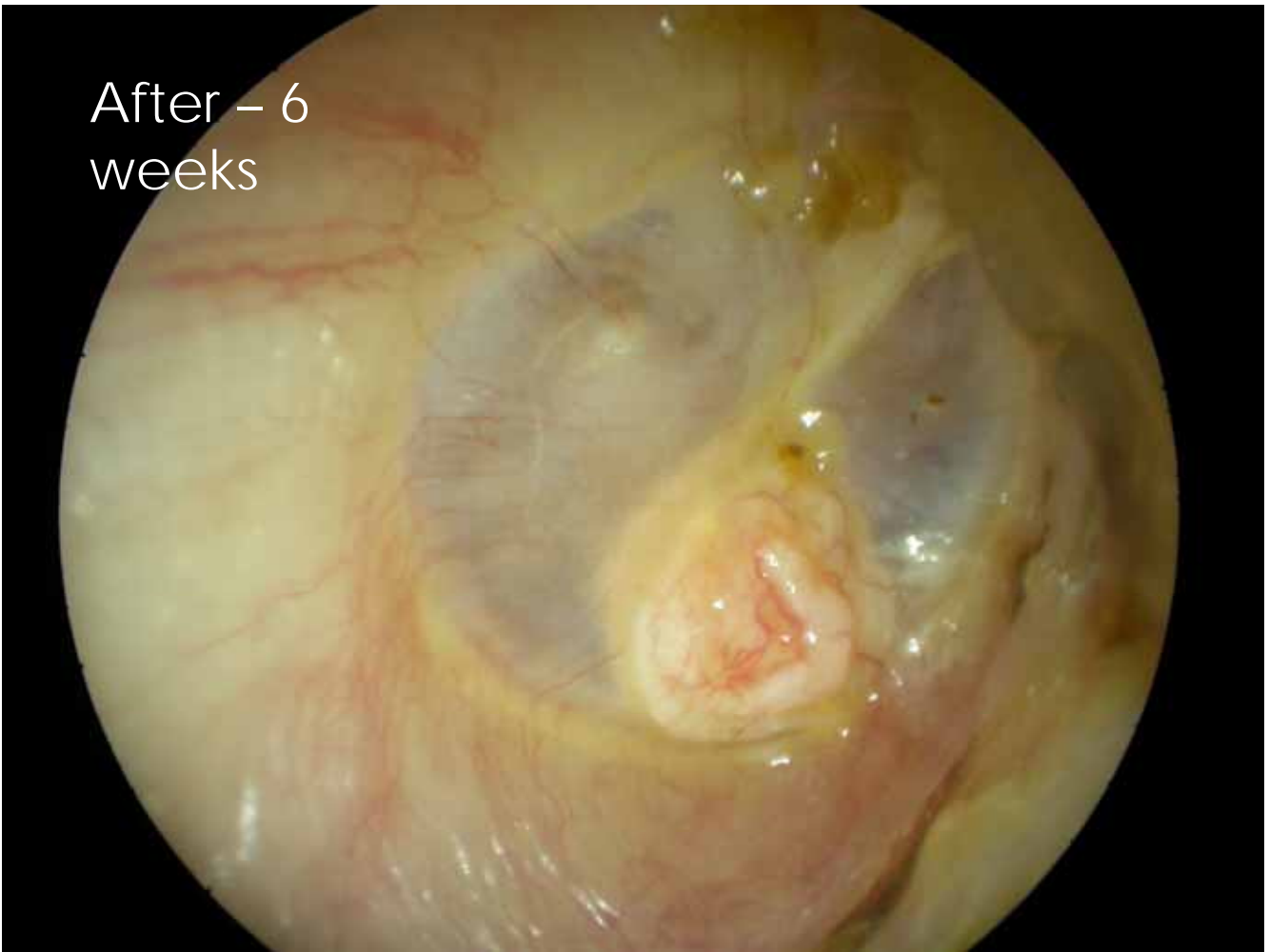
CW

- 35 F
- Intermittent discharge
- Smelly ear when infected
- Regular swimmer




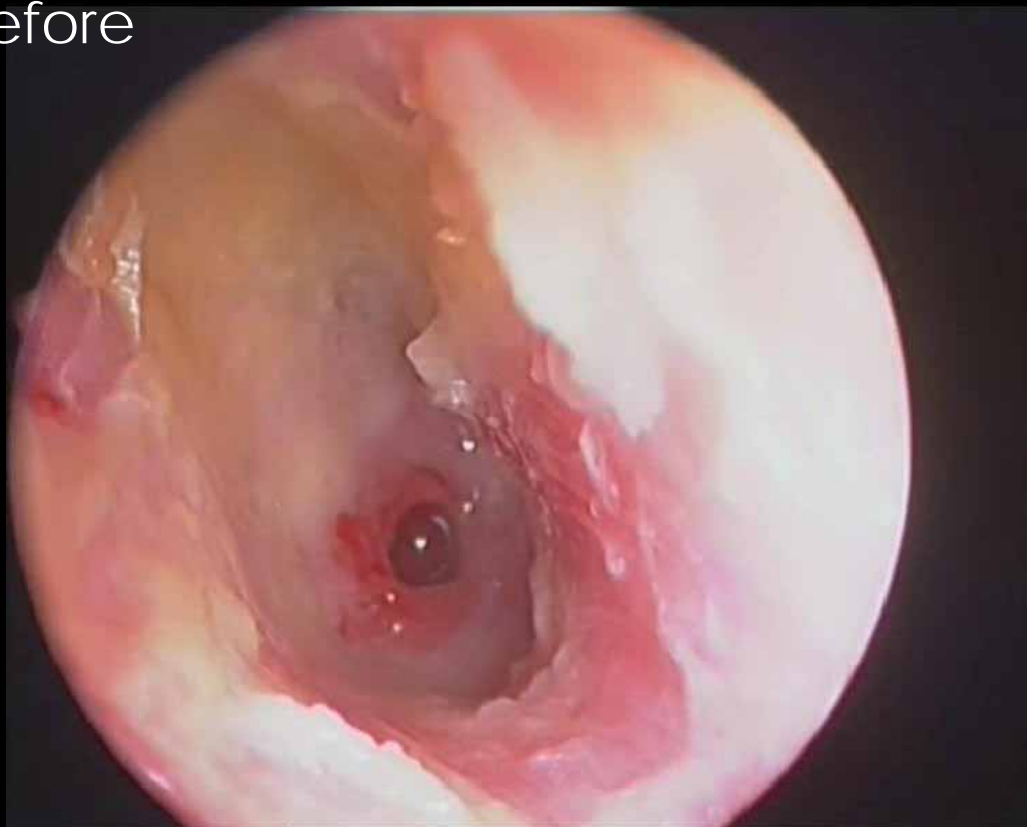
After – 6
weeks



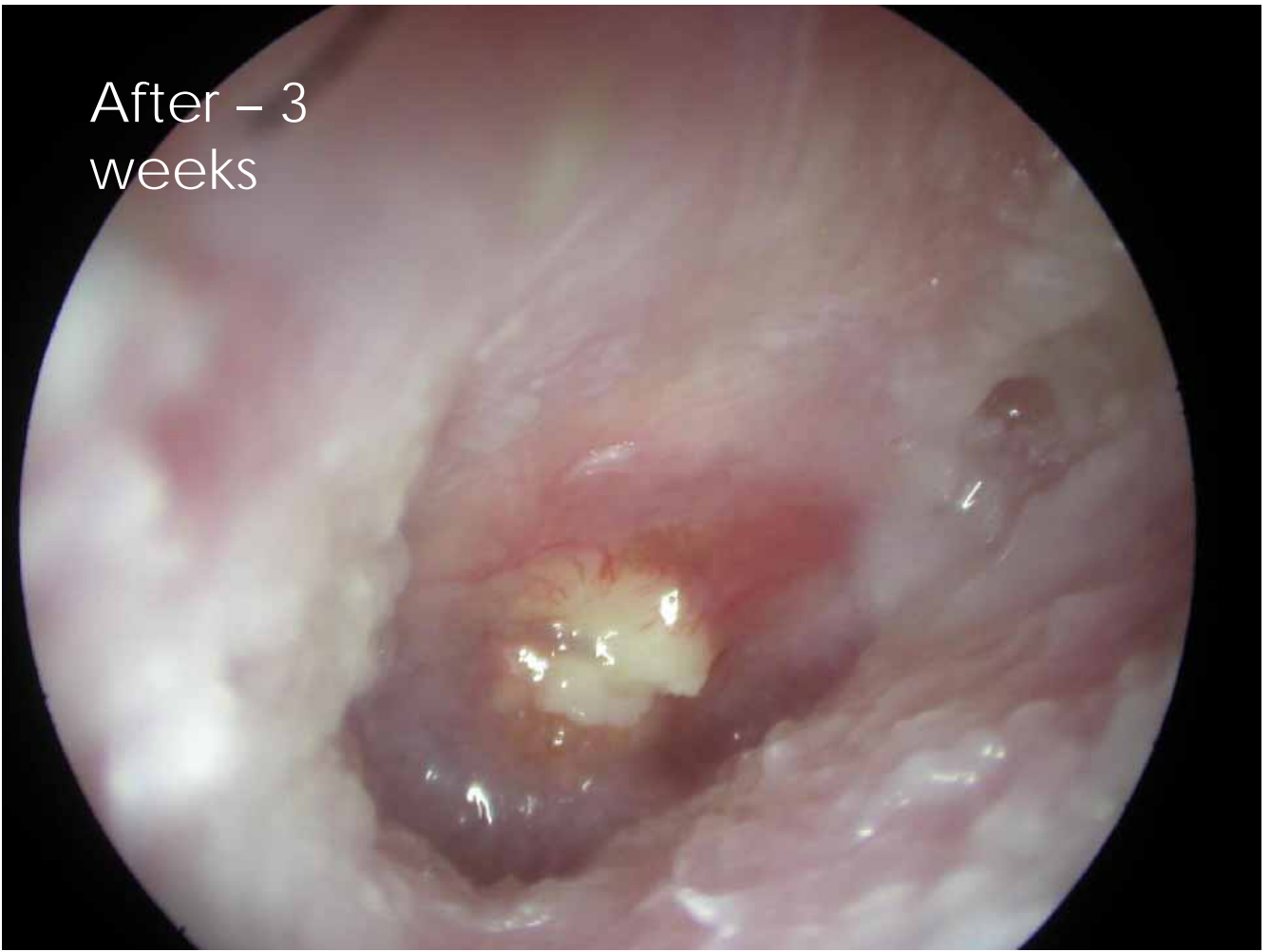
CW

- 35 M
- Persistent discharge
- Smelly ear
- No useable hearing

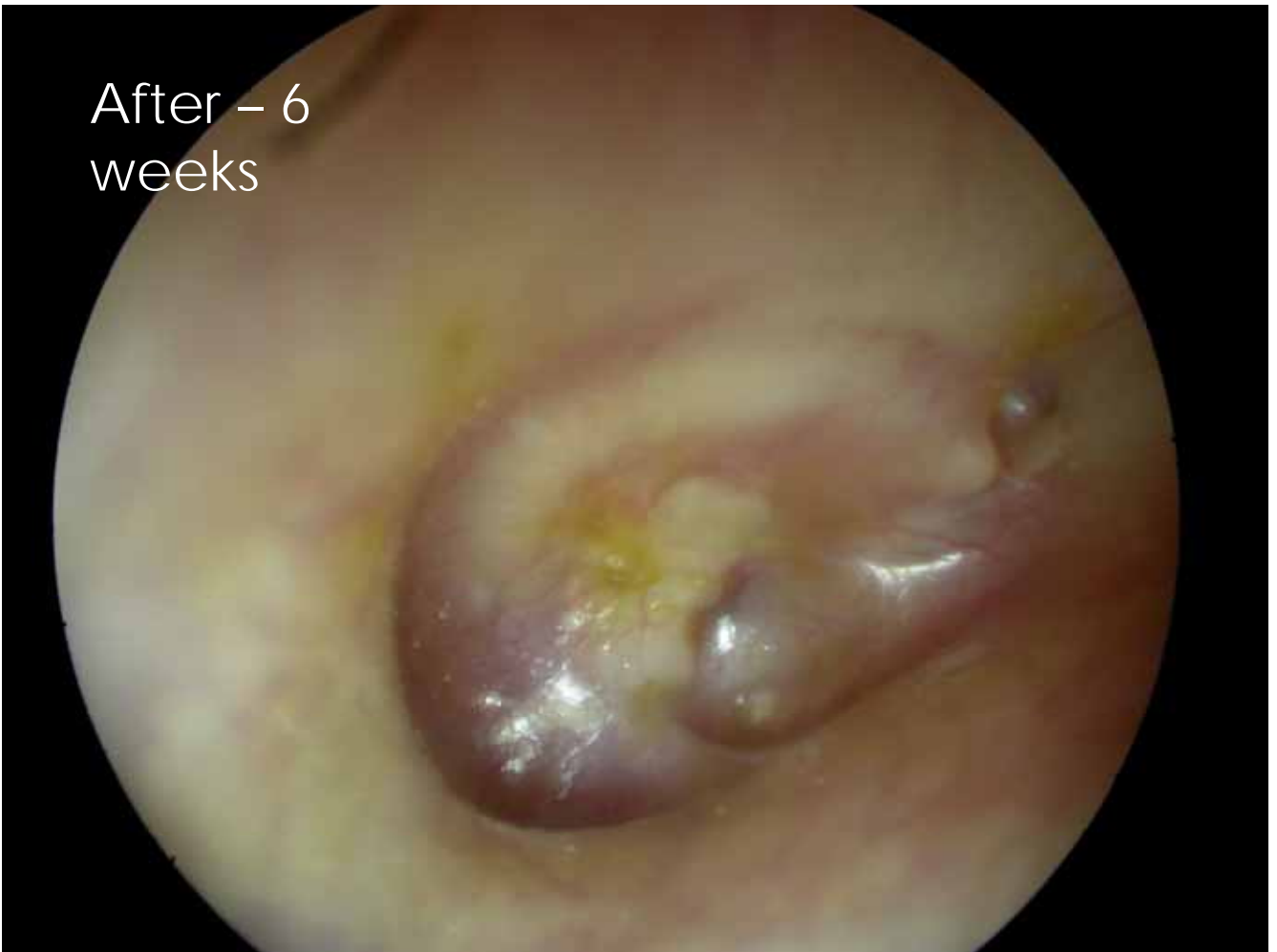Before



After – 3
weeks



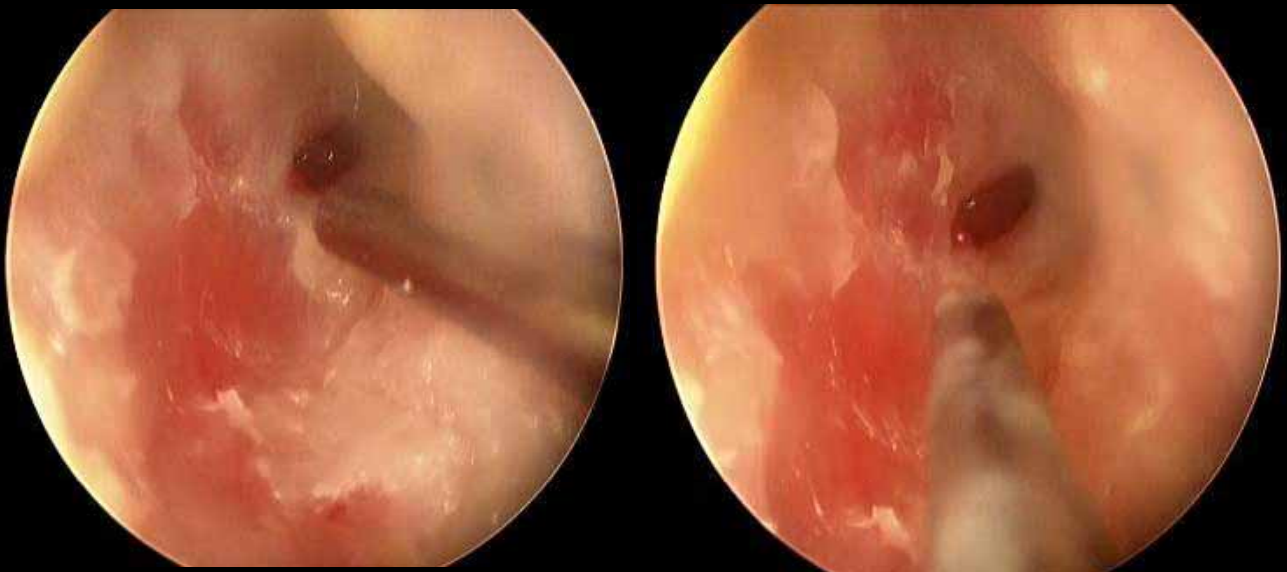After – 6
weeks



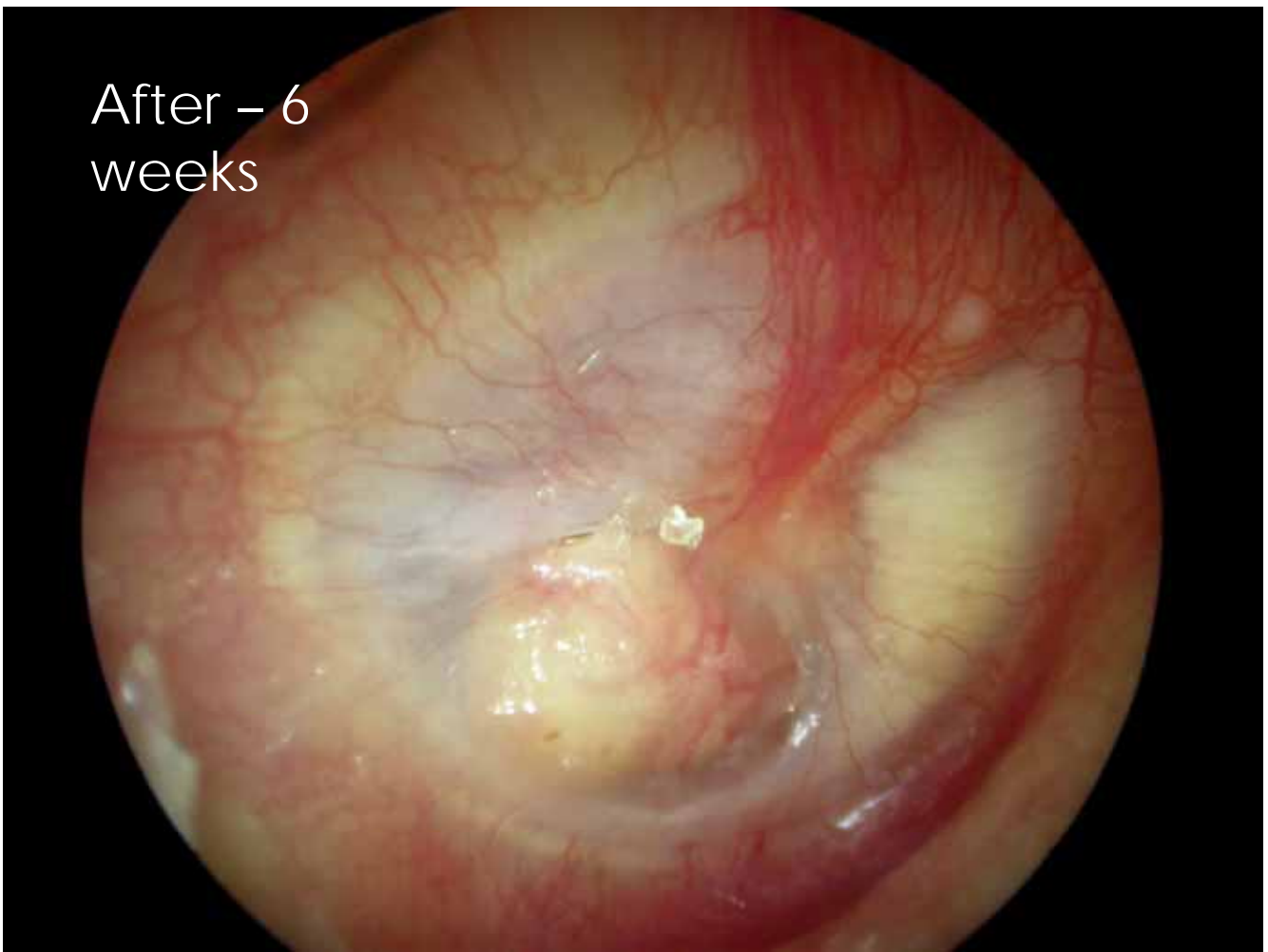
MP

- 45 F
- Persistent discharge
- Smelly ear
- Needs hearing aid on diseased side
- Poor contralateral hearing

Before



After – 6
weeks



Conclusions

- New technique of access to the middle ear
- New technique of grafting the TM
- Far less tissue trauma
- Day surgery more likely
- Patient-friendly