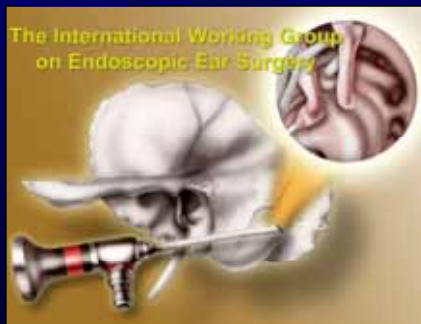




Evolution of the otoendoscopy in the middle ear surgery. From an additional to a primary procedure

Stéphane AYACHE

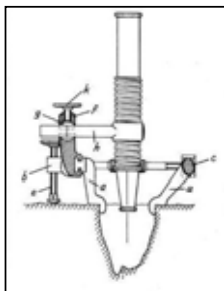


*ENT Departement
Clinique du Palais, Grasse - France*


Evolution of the otoendoscopy in the middle ear surgery. From an additional to a primary procedure



1911- 1922




Nylén



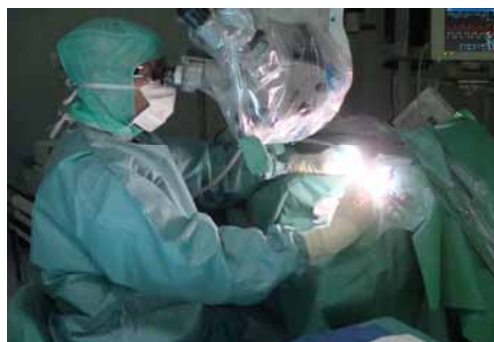Hömlgren

1935

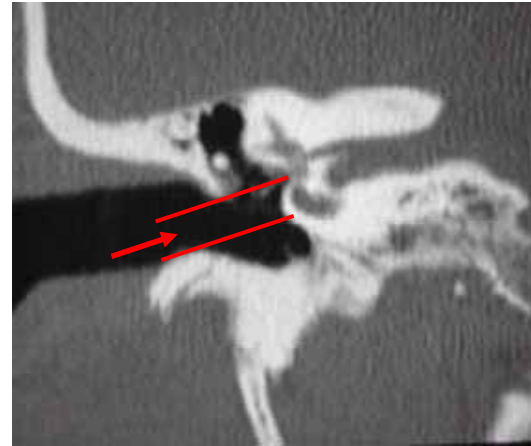
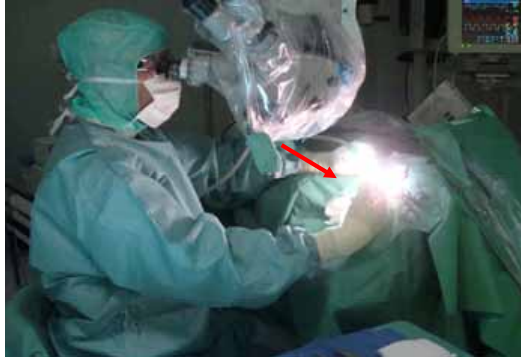

Sourdille

Today ...

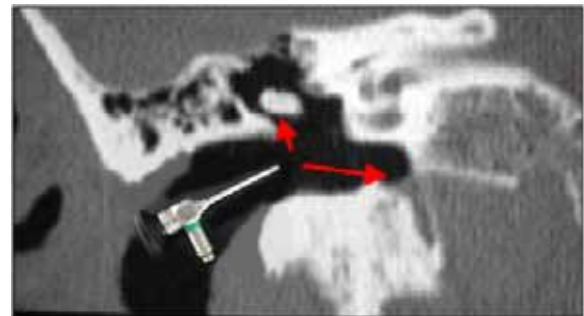
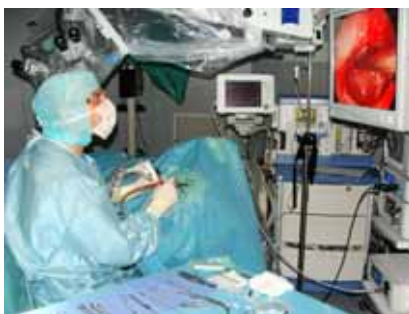

Otomicroscopy ...

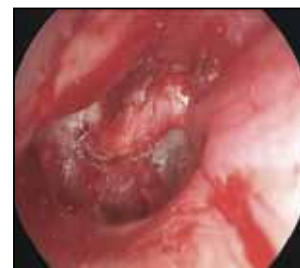
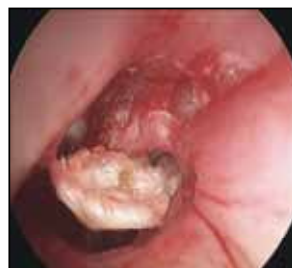
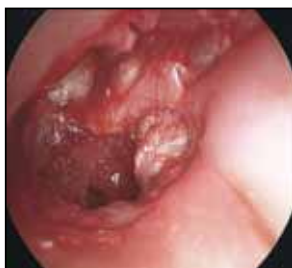... limited view, in the axis

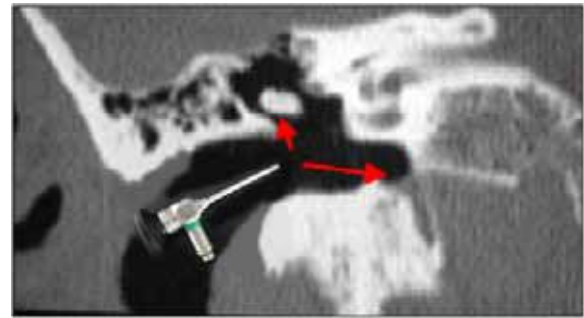
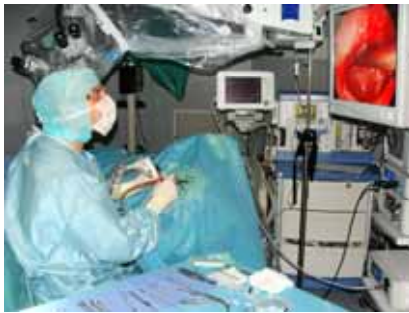Otoendoscopy ...



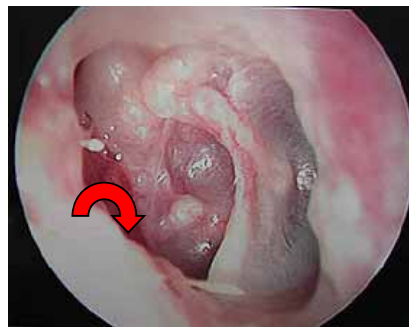
... wide field of view



Otoendoscopy ...



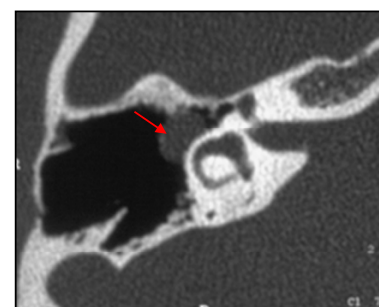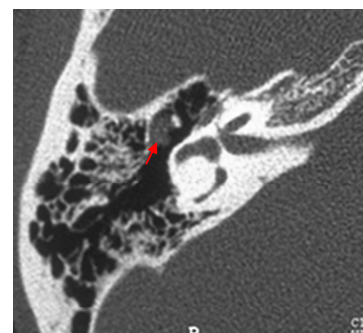
... and lateral access



Cholesteatoma and retraction pockets

➔ Development
of canal wall-up tympanoplasties

- less invasive
- more conservative
- but hidden anatomic regions
- and residual disease



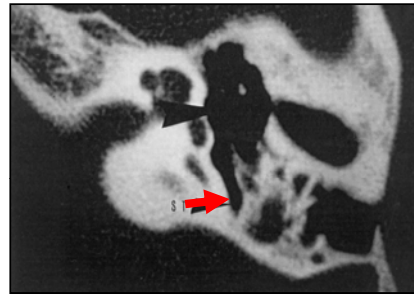
Cholesteatoma and retraction pockets

➔ Hidden anatomic regions

Rétrotympanum

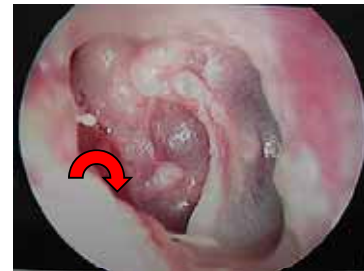
- Sinus tympani

(posterior tympanotomy)



- Facial Recess

(posterior tympanotomy, reaming of the posterior tympanal)

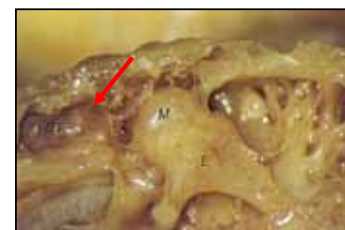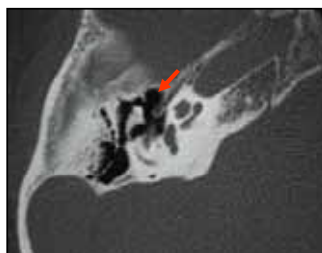

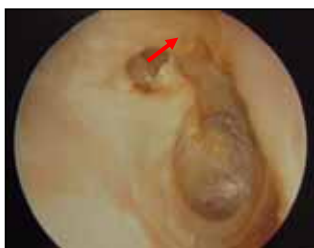
Cholesteatoma and retraction pockets

➔ Hidden anatomic regions

Anterior epitympanum *(supratubal recess)*

(wide atticotomy, antroatticomastoidectomy, removal and relaying of the external canal Babighian 1992)

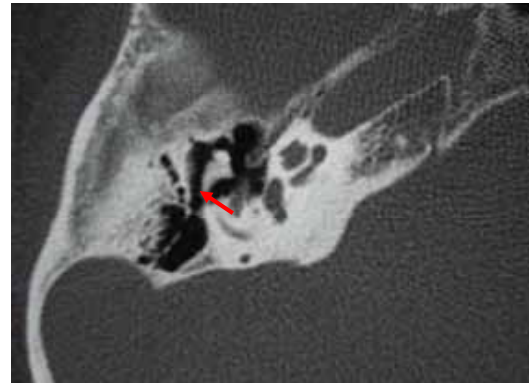
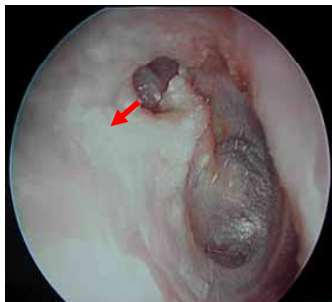

Cholesteatoma and retraction pockets

➔ Hidden anatomic regions

Posterior epitympanum (*transmeatal approach*)

(*wide atticotomy, antroatticomastoidectomy, removal and relaying of the external canal Babighian 1992*)

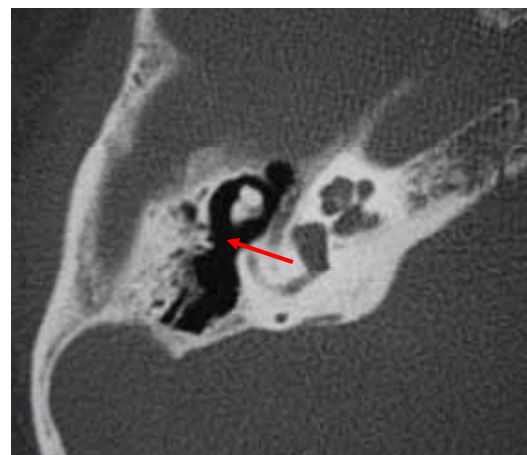
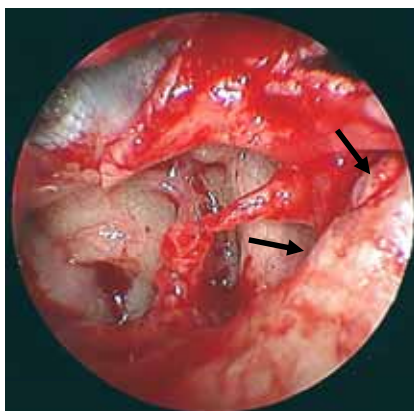


Cholesteatoma and retraction pockets

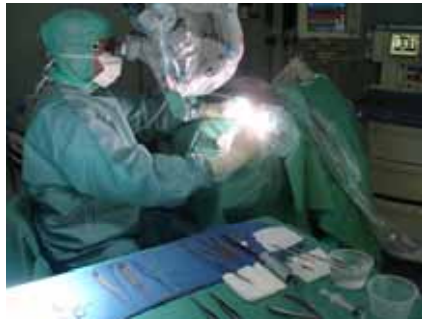➔ Hidden anatomic regions

Posterosuperior corner of the middle ear

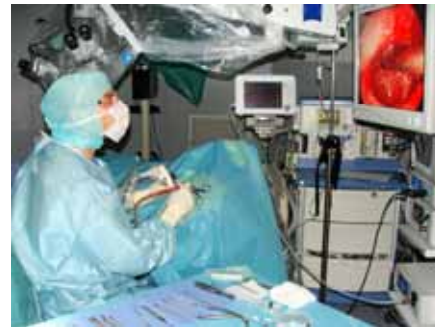(*wide posterior atticotomy, posterior tympanotomy with removal of the incus*)



Development of the additional otoendoscopy



Procedure under otomicroscopy



Control with otoendoscopy

Indications :

- hidden anatomic regions
- difficult local anatomic conditions

Additional otoendoscopy

Otoendoscopy in cholesteatoma surgery of the middle ear.

What benefits can be expected ?

S. AYACHE, B. TRAMIER, V. STRUNSKI

Otol Neurol 2008;29:1085-90

- 350 patients:
 - cholesteatoma and uncontrollable retraction pockets
 - CWU (transmeatal and antroatticomastoidectomy approach) and CWD procedures
- Otomicroscopy and control with otoendoscopy
- **peroperative residual disease**
 - anatomic region (epitympanum, retrotympanum)
 - quality of removal under otoendoscopy
- **residual cholesteatoma** in the follow-up

Additional otoendoscopy

Otoendoscopy in cholesteatoma surgery
of the middle ear.

What benefits can be expected ?

S. AYACHE, B. TRAMIER, V. STRUNSKI

Otol Neurol 2008;29:1085-90

- No more CWD tympanoplasty nor posterior tympanotomy
- high rate of per operative residual disease (44% epitympanum and 76% retrotympanum) but high rate of transmeatal approach

Additional otoendoscopy

Otoendoscopy in cholesteatoma surgery
of the middle ear.

What benefits can be expected ?

S. AYACHE, B. TRAMIER, V. STRUNSKI

Otol Neurol 2008;29:1085-90

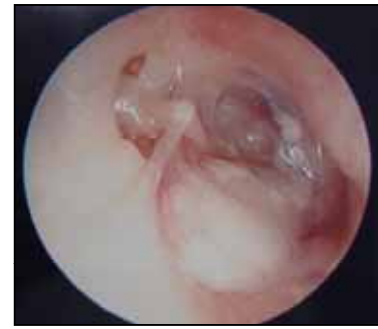- residual disease in the follow-up:
 - same frequency with or without otoendoscopy (literature)
 - but peroperative residual disease = residual disease in the follow-up
- residual as a pearl ++ (easier removal)
- better follow-up with CT-scan and MRI (region at risk)

Additional otoendoscopy

➔ Difficult anatomic conditions

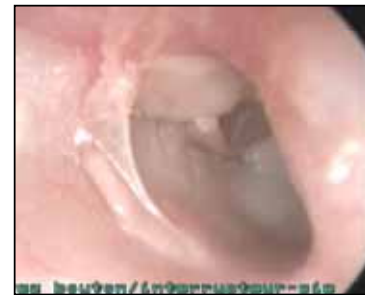19 year-old patient

- first stage tympanoplasty (cholesteatoma)



- second stage 12 months later

(MRI with diffusion: normal)



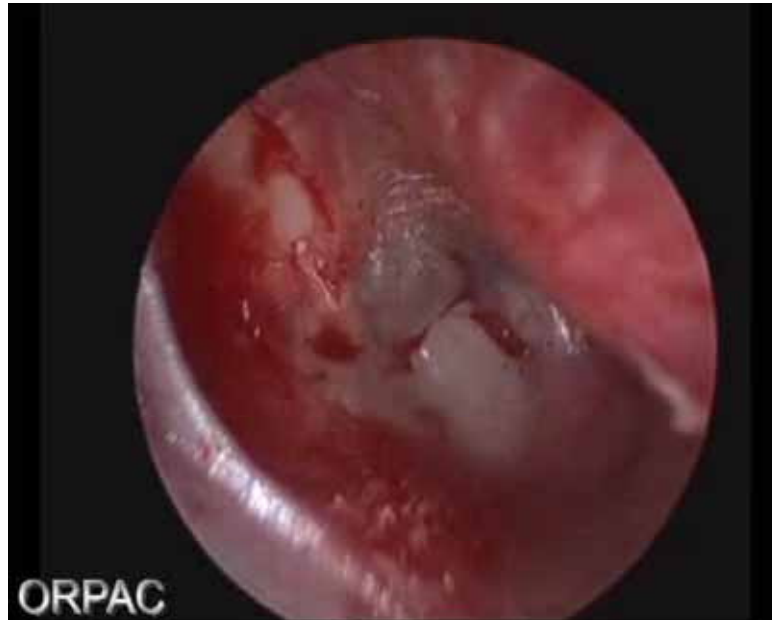Additional otoendoscopy

➔ Difficult anatomic conditions

- residual disease in the supratubal recess
- no conductive hearing loss
- malformation of the articulation between incus and stapes
- prociidence of the tegmen tympani
- objective : canal wall-up tympanoplasty

Additional otoendoscopy

➔ Difficult anatomic conditions



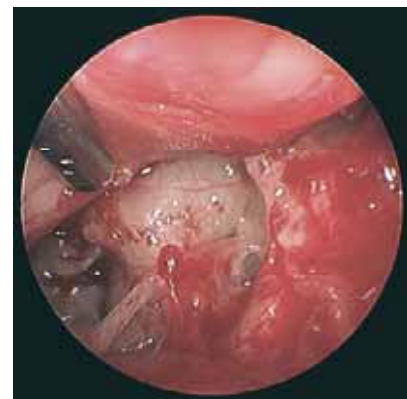Primary otoendoscopy

➔ Advance in the mini-invasive otology (transmeatal approach)

- Cholesteatoma and retraction pockets -

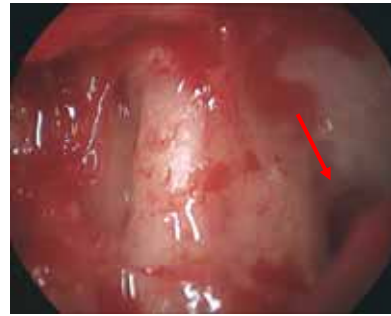• Retrotympanum

- prociidence of the posterior tympanal
- exposition to recess
- dissection of the stapes
- no posterior tympanotomy
- no CWD tympanoplasty
- value of the CT-scan (VII3 and monitoring)



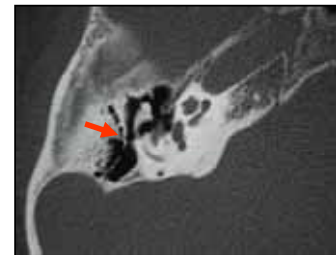
Primary otoendoscopy

- Cholesteatoma and retraction pockets -



• Epitympanum

- atticotomy (spontaneous or surgical)
- removal of the incus and head of the malleus
- limits :
 - aditus ad antrum (value of the pre-operative CT scan)
 - meningocele (pre-operative MRI)
 - intracranial extension (MRI)



Primary otoendoscopy

- Ear drum perforations -

Adipose graft.

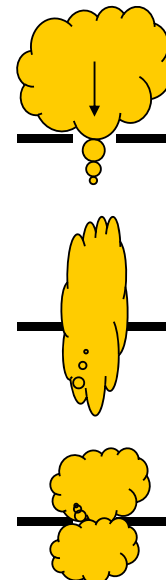
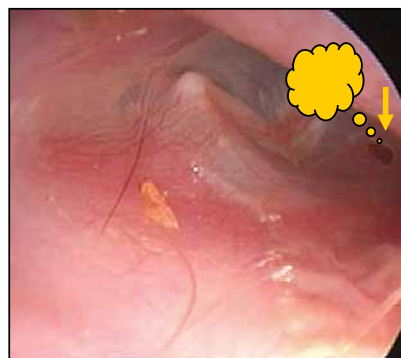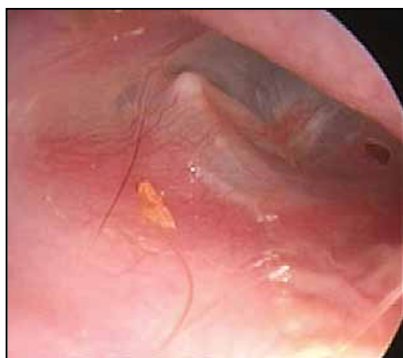An original option in myringoplasty

S. AYACHE, F. BRACCINI, F. FACON, JM. THOMASSIN

Otol Neurol 2003;24:158-64

➡ Adipose graft

Small perforations



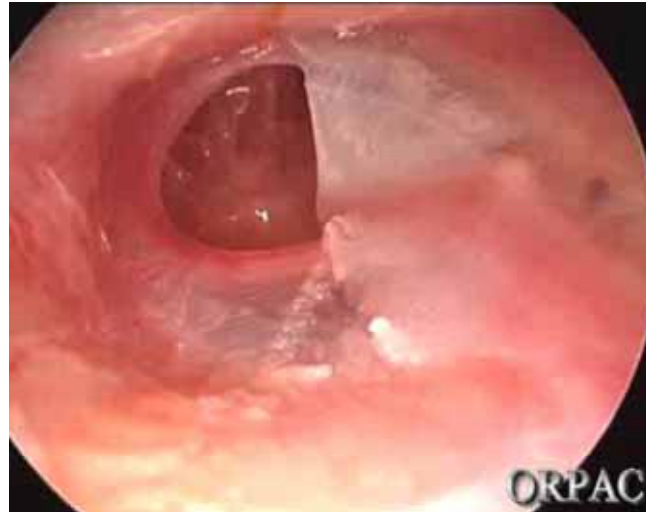
« Champagne cork »

Primary otoendoscopy

- Ear drum perforations -

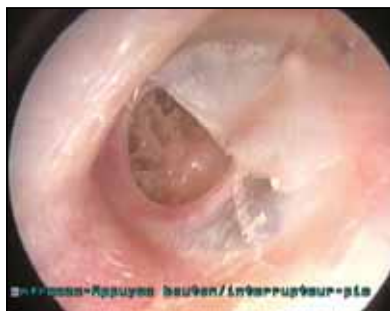➔ Myringoplasty (*temporal aponevrosis, perichondrium, cartilage*)

No limit of size

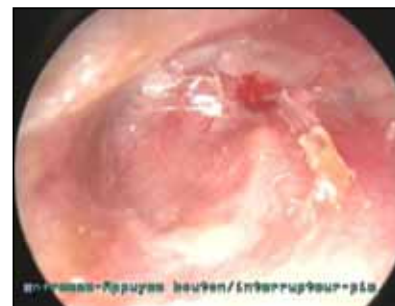


Primary otoendoscopy

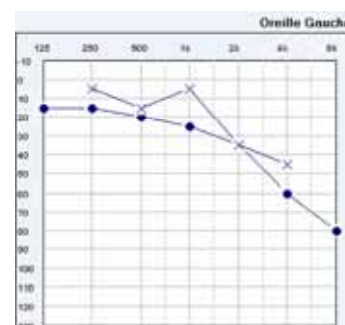
- Ear drum perforations -



Pre-operative



Post-operative (2 months)



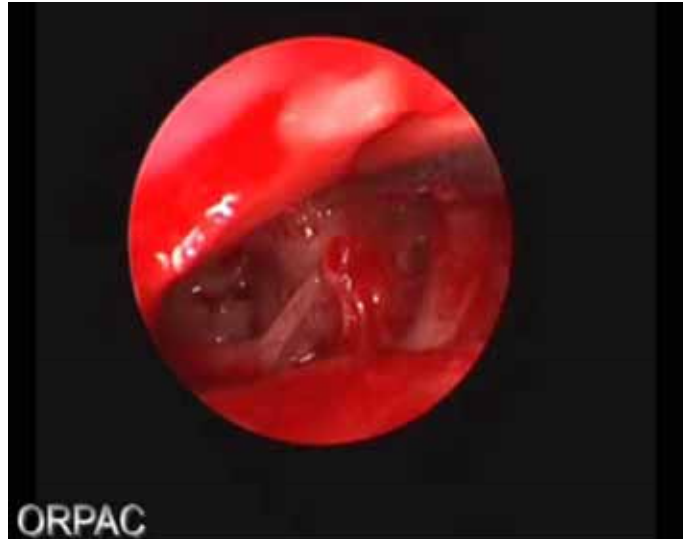
Primary otoendoscopy

- Ossiculoplasty -

➔ With the stapes

- *myringostapedopexy*

- *double cartilage*



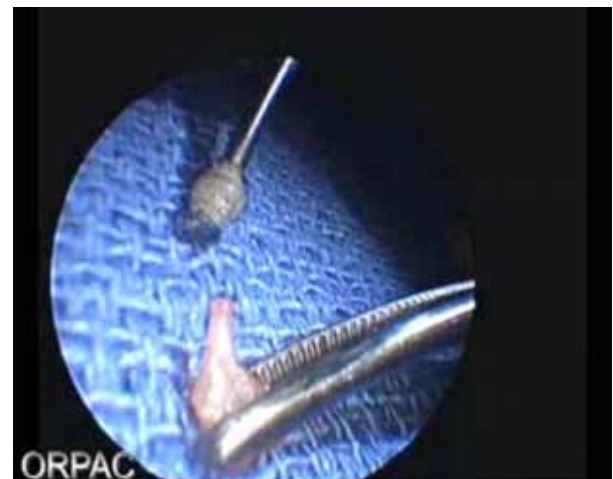
Primary otoendoscopy

- Ossiculoplasty -

➔ With the stapes

- *ossiculoplasty with the incus*

(*modelling with the otomicroscope*)

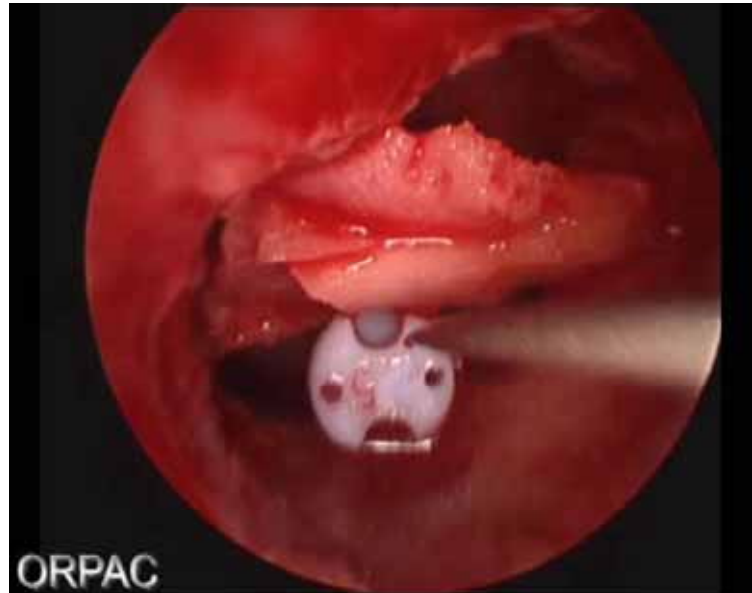


Primary otoendoscopy

- Ossiculoplasty -

➔ With the stapes

- *Partial prosthesis*
(no blood in the external auditory canal)

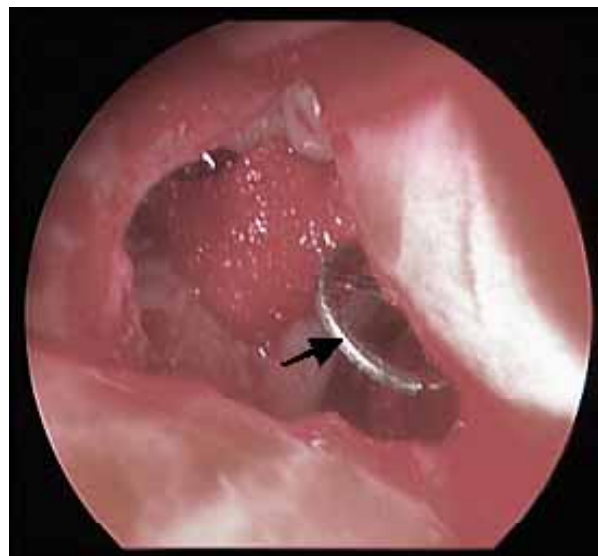

Primary otoendoscopy

- Ossiculoplasty -

➔ Without the stapes

- *total prosthesis*



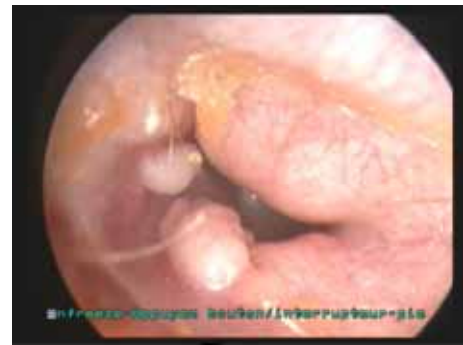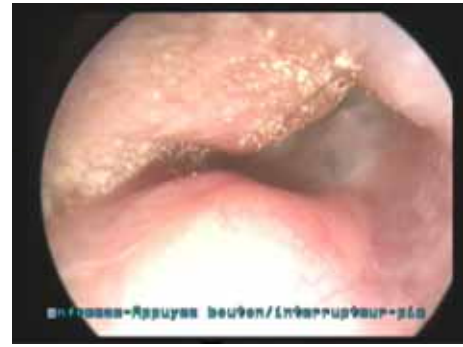Primary otoendoscopy

- limits of the procedure -

➔ Diameter of the external auditory canal

- big prociidence of the tympanal

- osteoma



Primary otoendoscopy

- limits of the procedure -

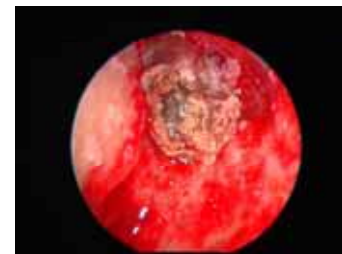
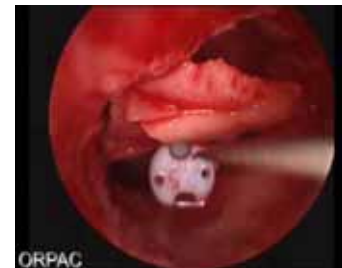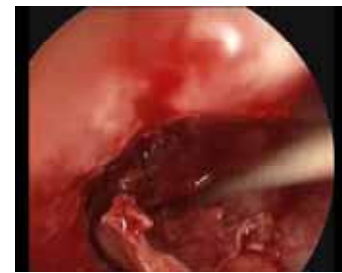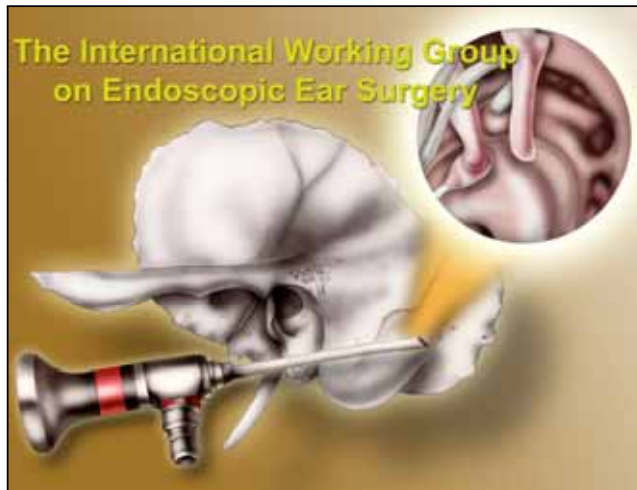
➔ Bleeding

- during the meatal flap dissection

- very reduced in the middle ear cavity

- no blood pressure variations (*coordination with anaesthetists*)

- non inflammatory ear



www.endoscopicearsurgery.com

27 - 28 NOVEMBRE 2009
GRASSE, France

Endoscopie ORL 2009
ENT Endoscopy 2009

Otologie, Otoneurochirurgie, Rhinologie
Laryngologie, Chirurgie cervicale et thyroïdienne,
Chirurgie des glandes salivaires

"PRE-PROGRAMME"

ORGANISATION
Package Organisation - Marseille

COORDINATION SCIENTIFIQUE
Dr Stéphane AWACHE
ORPAC, Grasse

PARTENARIAT SCIENTIFIQUE

- International Working Group on Endoscopic Ear Surgery
- International Salivary Gland Society
- European Stenotomology Training Centre
- Institut St. Pierre

PACKAGE

www.endoscopy2009.com

The poster features a background image of a town and a statue. It includes logos for the International Working Group on Endoscopic Ear Surgery, International Salivary Gland Society, European Stenotomology Training Centre, and Institut St. Pierre.

