



# New Technique For Endoscopic DCR

---

**Magdy Abdallah**  
**Prof. ENT, Zagazig**  
**University**  
**2010**



## ***INTRODUCTION***

---

External DCR was first described by **Toti** . various approaches have been described for this operation.

The concept of endonasal (DCR) was introduced by **Caldwell** .

**West** .using endonasal approach for DCR resembles the operation performed today.

The advent of endoscopic instrumentation for nasal and sinus surgery has renewed interest in intranasal DCR



# Endoscopic approach advantages

---

Identifying and correction of common intranasal causes of DCR failure :

Adhesions,

Enlarged middle turbinate,

Ethmoid sinus disease,

Deviated septum or

Other pathological causes[5].

MAGDY ABDALLAH 2010  
ZAGAZIG



## LASER DCR

---

The laser assisted endoscopic DCR was first reported nearly 20 years ago with experimental cadaveric case .

MAGDY ABDALLAH 2010  
ZAGAZIG




# TYPES OF LASERS

---

YAG,  
ND : YAG,  
Argon,  
CO2,  
KTP and  
Diode laser with different modification but no body  
can neglect the **high cost** of these  
procedures especially in the developing countries.


MAGDY ABDALLAH 2010  
ZAGAZIG



In this study, a new and economic  
technique was described for DCR  
aiming for the advantages of avoiding  
external scar , disruption of pumping  
mechanism of the external operation,  
and done by low cost tools under direct  
endoscopic control.

MAGDY ABDALLAH 2010  
ZAGAZIG

## ***PATIENTS AND METHODS***



Eleven patients complaining of obstructive epiphora of one side were chosen from the outpatient clinic of Ophthalmology and Otorhinolaryngology Department at Zagazig University Hospitals from the period of January 2000 to December 2008, their age ranged from 17 to 56 years, seven patients were females and four were males. After history taking; including the nature of epiphora and any eye discharge, nasal obstruction, nasal discharge, epistaxis and any previous nasal operation , they were subjected for the following :

MAGDY ABDALLAH 2010  
ZAGAZIG

### **1- Ophthalmological examination**



Regurge test

Dye disappearance test (DDT)

Jones dye tests; Jones I and Jones II

Endoscope increase test sensitivity.

MAGDY ABDALLAH 2010  
ZAGAZIG



## 2- Nasal endoscopy

---

Inferior meatus for any masses,  
Middle meatus for signs of sinusitis including polyposis and mucopurulent discharge,  
Septal deviation,  
Enlarged middle or inferior turbinate,  
Prominent agger nasi cells.

MAGDY ABDALLAH 2010  
ZAGAZIG




## 3- Radiological examination

---

**CT** for paranasal sinuses (both axial and coronal views) for identification of a pre-existing sinus disease or anatomic abnormalities not recognized on physical examination.


**Dacryocystogram** : Radioopaque contrast media (lipidol) is injected into the canaliculi while an x-ray is taken. Dye should flow through the duct and drain into the nasopharynx if no obstruction was present. When an obstruction was present, a dilated lacrimal sac is often observed proximal to obstruction. Filling defect lacrimal stones, or lacrimal tumors should be excluded, and the site of obstruction was determined.

MAGDY ABDALLAH 2010  
ZAGAZIG



Then, patients were prepared for surgery under local or general anesthesia. Those who had general anesthesia were prepared by complete blood picture analysis, chest and heart assessment, renal and hepatic evaluation and CNS examination.

MAGDY ABDALLAH 2010  
ZAGAZIG




## DCR Surgical technique

Under local or general anaesthesia.  
Using 2.7 m or 4 mm diameter endoscope

The smallest size (24 g) intravenous Teflon canula was used to pass through the punctum (after the inner trocar has been withdrawn out)


perpendicular to the lid margin gently till resistance was found after 2 mm distance,

MAGDY ABDALLAH 2010  
ZAGAZIG




Then it enter the sac, more medial gentle pressure was applied to meat the bone of lacrimal fossa, and bone resistant was felt then the direction was changed to be parallel to lid margin and gentle pressure was applied to be introduced medially for about 8 mm.

MAGDY ABDALLAH 2010  
ZAGAZIG



Hence the inner trocar was introduced through the canula to meet the medial bony wall of lacrimal fossa and its direction was adjusted to meet the posterior thin part of the lacrimal fossa.


MAGDY ABDALLAH 2010  
ZAGAZIG



A monopolar diathermy probe (20-40 W), was applied

Touching the outer end of the inner trocar while the assistant introduce the nasal endoscope towards the anterior end of middle turbinate with a blunt suction tip.

MAGDY ABDALLAH 2010  
ZAGAZIG




Smoke was found at the area of lacrimal fossa and fills the nasal cavity,

Suction of this smoke and gentle medial pushing of trocar led to appearance of the medial end of the trocar tip nasally.


MAGDY ABDALLAH 2010  
ZAGAZIG





Another applications of diathermy might be used to make a wider opening anterior, posterior, superior or inferior under endoscopic control  
Intranasal microdrill might be used to make a wide bony opening anteriorly where thick bone is present.


MAGDY ABDALLAH 2010  
ZAGAZIG



**Mitomycin-C** 0.2 mg/ml solution was applied using cotton tipped rod and washed by saline after 5 minutes.

**Silicon tympanostomy** ventilation T-tube size 2 using curved ear forceps to put it in the sac with the horizontal limbs in the sac and the vertical limb free in the nose.

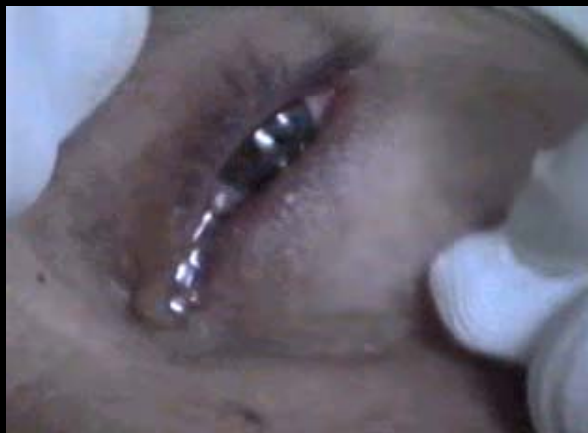MAGDY ABDALLAH 2010  
ZAGAZIG



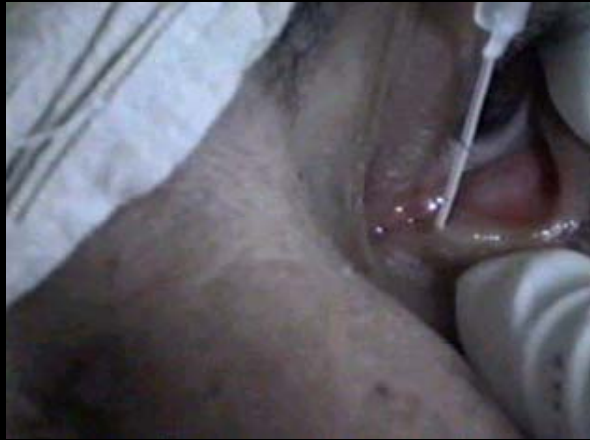
Fluorescein drops in eye was applied to make sure that patency was achieved and its color was seen to pass freely through the vertical limb to the nose. Corticosteroid-antibiotic eye drops was used.

Nasal packing was used in cases where septoplasty was done.

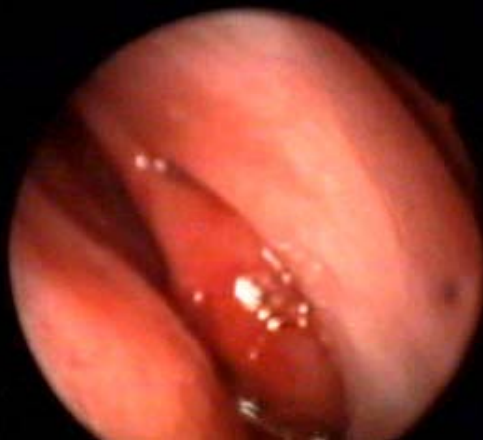
MAGDY ABDALLAH 2010  
ZAGAZIG



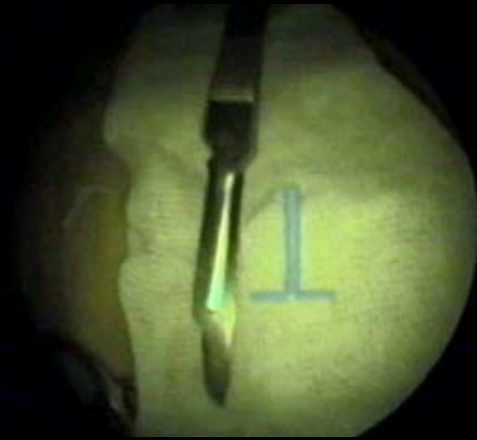

MAGDY ABDALLAH 2010  
ZAGAZIG



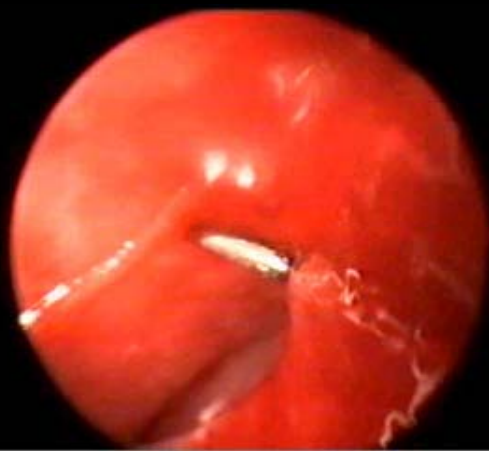

MAGDY ABDALLAH 2010  
ZAGAZIG



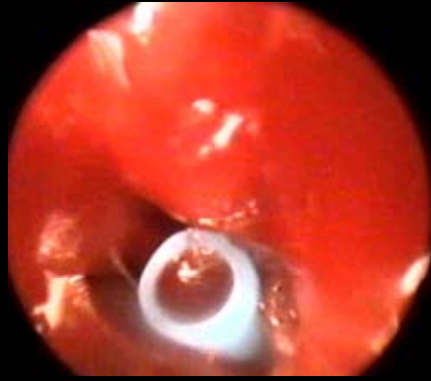
MAGDY ABDALLAH 2010  
ZAGAZIG



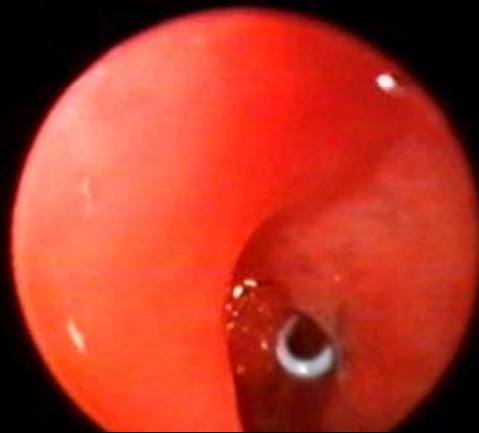
MAGDY ABDALLAH 2010  
ZAGAZIG



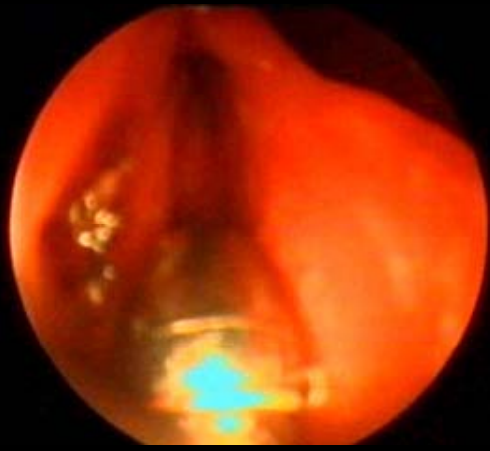
MAGDY ABDALLAH 2010  
ZAGAZIG



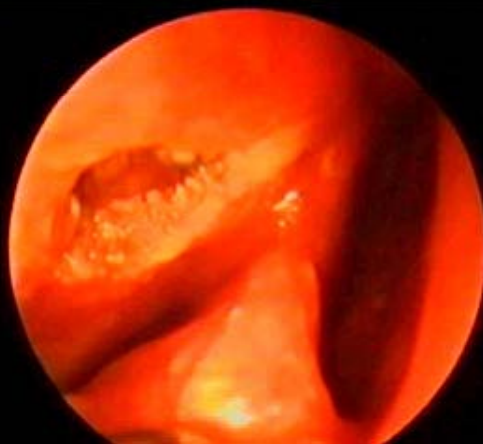
MAGDY ABDALLAH 2010  
ZAGAZIG



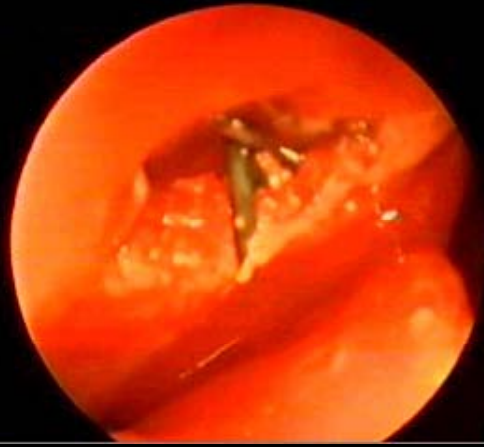
MAGDY ABDALLAH 2010  
ZAGAZIG



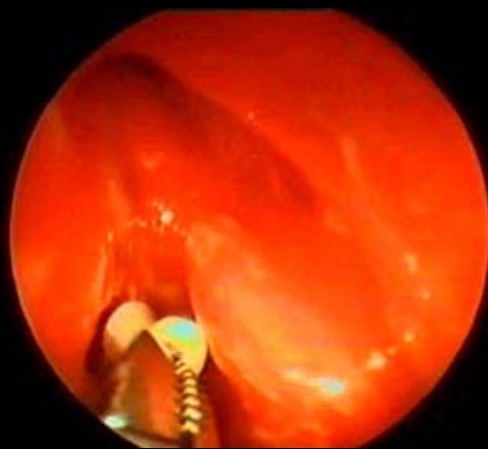
MAGDY ABDALLAH 2010  
ZAGAZIG



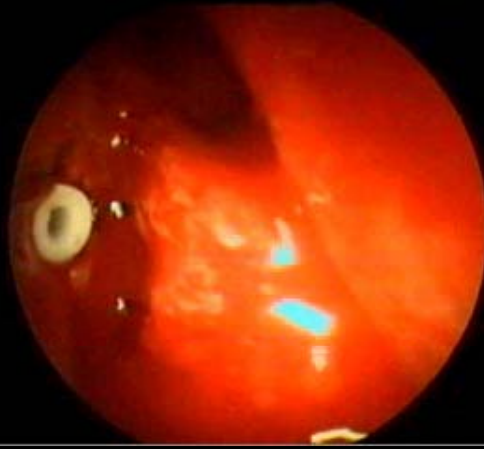

MAGDY ABDALLAH 2010  
ZAGAZIG



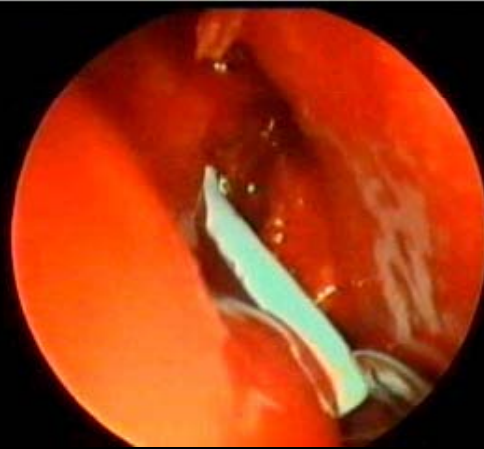
MAGDY ABDALLAH 2010  
ZAGAZIG



MAGDY ABDALLAH 2010  
ZAGAZIG

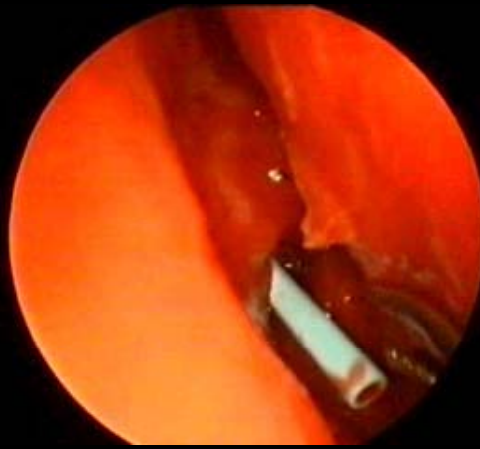

MAGDY ABDALLAH 2010  
ZAGAZIG



MAGDY ABDALLAH 2010  
ZAGAZIG






MAGDY ABDALLAH 2010  
ZAGAZIG

## postoperative follow up

The patients were seen in the 2nd day postoperatively and then weekly for one month. Corticosteroid-antibiotic eye drops was used in each visit.

Then the patients were seen monthly for at least 6 months

MAGDY ABDALLAH 2010  
ZAGAZIG



. In every visit the patients were asked about the symptoms of epiphora DDT and Jones tests were done to assess the physiology of the lacrimal passage. Irrigation and nasal endoscopy were done to assess the anatomical patency of the opening.

The patients uses antibiotic-steroids eye drops four times daily and local steroid spray intranasal twice daily for 2 weeks.


MAGDY ABDALLAH 2010  
ZAGAZIG



## ***RESULTS***


Seven female patients and four males were included in this study. Their age ranged from 17 years to 56 years with the mean of 29 years.

MAGDY ABDALLAH 2010  
ZAGAZIG



Regurge test was positive in all cases and DDT showed delayed clearance of the dye in all cases. Jones I test showed obstruction in all cases. Jones II test showed high grade obstruction in 10 cases and partial obstruction in one case.

MAGDY ABDALLAH 2010  
ZAGAZIG




Endoscopic nasal examination showed Deviated septum in 2 cases toward the side of obstructive epiphora.

Mucopus in the middle meatus in 4 cases,  
Prominent agger nasi cells in one case,

Inferior turbinate suspicious enlargement in one case (proved to be inflammatory histopathologically).

MAGDY ABDALLAH 2010  
ZAGAZIG



Dacryocystogram showed obstruction in all cases with dilated sac in nine cases, but no stones nor masses were seen as filling defects.

CT scan showed deviated septum in 2 cases chronic ethmoiditis (mucosal thickening), maxillary sinusitis (mucosal thickening) in one case, enlarged inferior turbinate soft tissue in one case, prominent agger nasi cells in one case.

MAGDY ABDALLAH 2010  
ZAGAZIG




Operatively no major complications

Three patients underwent the operation under local anaesthesia while eight under general anaesthesia.


Two cases had septoplasty prior to DCR. Four cases had unilateral endoscopic sinus surgery (3 cases of them had ethmoidectomy, and one middle meatal antrostomy).

MAGDY ABDALLAH 2010  
ZAGAZIG




Nasal packing was used in 2 cases where septoplasty was done. In one of them, the T-tube was accidentally slipped on removal of the nasal pack, and the opening was restenosed again after 2 months and was needed revision surgery.

MAGDY ABDALLAH 2010  
ZAGAZIG




7 patients had completed the 6 months follow-up period at least, 4 patients completed 18 months, 3 patients completed 12 months and 2 patients completed 6 months. One patient was lost in follow up

MAGDY ABDALLAH 2010  
ZAGAZIG



.Nine patients expressed absence of epiphora during the follow up period, as DDT and Jones I tests were done every visit revealed normal physiological lacrimal function for them. So, the success rate was 90%. Irrigation of the lacrimal passage in every visit showed patent pathway in the followed up patients.

MAGDY ABDALLAH 2010  
ZAGAZIG



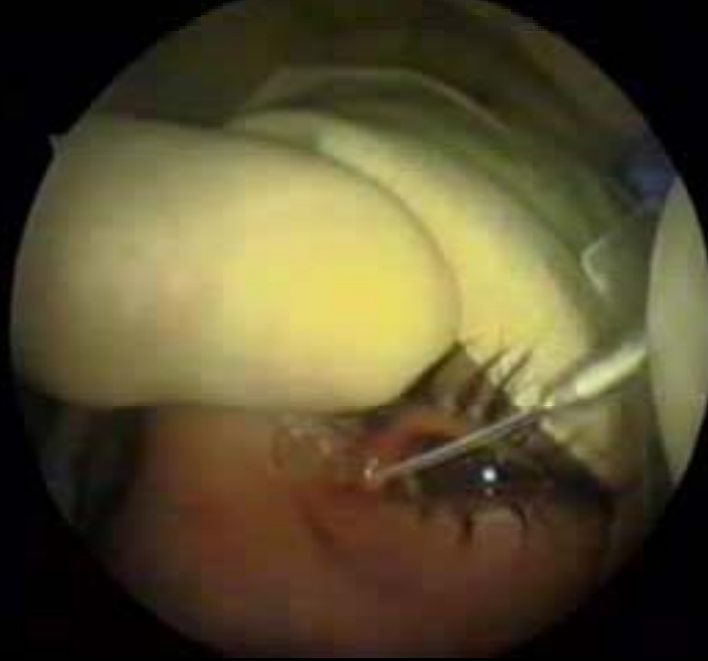Nasal endoscopy was done in every follow-up visit and patency of ostium was examined as follows:

- Four patients had patent ostium for 18 months.
- Three patients had patent ostium for 12 months.
- Two patients had patent ostium for 6 months.
- One patient had stenosed ostium after 2 months.
- One patient was lost.

MAGDY ABDALLAH 2010  
ZAGAZIG



## SHORT VIDEO DCR




MAGDY ABDALLAH 2010  
ZAGAZIG



## Endoscopic DCR advantages

Minimally invasive surgery  
Avoidance of a cutaneous incision,  
Conservation of lacrimal pump  
Avoidance of injury of medial cathal ligament  
Better visualization and treatment of the  
nasal causes of lacrimal obstruction or  
DCR failure.

MAGDY ABDALLAH 2010  
ZAGAZIG



**Onerci** refused preferring laser DCR as the first operation due to the high cost, longer operation time, and less satisfactory results. It may be an alternative in cases with a tendency bleeding. However, the high cost of all laser machines does not permit its use on a large scale in the developing countries.

**Cokkeser** reported high success rate with endoscopic hammer-chisel non-laser DCR technique, the same as endoscopic DCR with use of laser.

MAGDY ABDALLAH 2010  
ZAGAZIG



## ***CONCLUSION***

Minimally invasive surgery,  
Encouraging results with mucosa and bone conservation  
No major complications.

Local or general anaesthesia,  
Suitable in the developing countries as it needs low cost instrumentation.


**NO need for light probe, or laser** ( expensive tool).

Start at the posterior thin lacrimal bone

The maxillary bone that forms the anterior aspect of the lacrimal fossa is relatively thick bone and considered the most difficult to drill

MAGDY ABDALLAH 2010  
ZAGAZIG






---

In the standard endoscopic DCR surgery the sac opening is enlarged to 5-10 mm in diameter, as enough of the medial sac wall should be removed to be able to view the internal common punctum with the 30 endoscope. The location of the common punctum is verified by passing stents attached to a silicone tubing through the superior and inferior canaliculi, these stents are grasped and withdrawn from the nasal cavity and cut from the tubing and then are tied and trimmed within the nose so as to form a continuous loop around the canaliculi, for the length of the follow-up period (6 months) [22,23,24]. However,


MAGDY ABDALLAH 2010  
ZAGAZIG



---

Conservative for mucosa and bone, so no more need for removal of about 10 mm of mucosa and bone. The T-tube is about 2 mm in diameter. So, only less than 3 mm of mucosa and bone is removed, leaving the rest of the job for mitomycin-C application that will prevent restenosis


MAGDY ABDALLAH 2010  
ZAGAZIG



T-tube is hollow and has a lumen which drain tears in the sac soon postoperatively on contrast to the Guibor canaliculus intubation stent which has no lumen.

Avoiding foreign body sensation in the puncti as it was with old stenting one.

MAGDY ABDALLAH 2010  
ZAGAZIG




There were no probability of missing any anatomical landmarks, no major complications are encountered, easiness of the technique to be performed under local or general anaesthesia, and a technique with a low cost instrumentation as there is no need for the expensive laser machines. All above advantages make this technique a promising one in the developing countries.

MAGDY ABDALLAH 2010  
ZAGAZIG



Thank You



In standard endoscopic DCR technique, 20 gauge fiberoptic light probe is needed to pass through a canaliculus into the lacrimal sac, to transilluminate the lateral nasal wall, providing information about the location of the lacrimal sac [13,14]. The area of maximal brightness corresponds with the posterior part of lacrimal sac where overlying bone is thinnest, not the center of the sac [15]. The light probe is an expensive tool. Also, in standard endoscopic DCR technique, the maxillary bone that forms the anterior aspect of the lacrimal fossa must be removed. Removal of this relatively thick bone is technically considered the most difficult step of the surgery. Bone removal may be accomplished with a drill, curette, or backbiting forceps [16]. Because of the limitations with conventional instrumentation, the surgical laser has become a popular tool for the standard endoscopic DCR technique to facilitate bone removal and haemostasis. Although the argon [6], carbon dioxide [17] and potassium titanyle phosphate KTP [17,18] laser has been used for transnasal endoscopic DCR, the holmium: YAG laser is particularly well suited for this procedure because of properties of fiberoptic delivery, effective bone-cutting capabilities and precise soft tissue coagulation [19,20].

# DISCUSSION

The advent of endoscopic instrumentation for nasal and sinus surgery has prompted renewed interest in intranasal DCR [4]. Endoscopic DCR is a well-established alternative choice for external DCR for treatment of obstruction of the lacrimal pathway and have a success rate of up to 95% in primary cases [7]. Endoscopic DCR has the advantages of being minimally invasive surgery with avoidance of a cutaneous incision, conservation of lacrimal pump mechanism, avoidance of injury of medial cathal ligament [8,9] and better visualization and treatment of the nasal causes of lacrimal obstruction or DCR failure. Hartikainen et al [9] concluded that the success rate of the traditional external DCR, when compared with that of the endonasal endoscopic DCR, are equal indicating that these two different DCR techniques are acceptable alternatives. Also, Cokkeser et al [10] reported that the success rate of the endoscopic DCR procedure is comparable with that of traditional external DCR. As well as, Dietrich et al [11] recommended that the endonasal approach is a safe and reliable procedure in the management of nasolacrimal duct obstruction and is an alternative to the traditional external route. On the other hand, Zilelioglu et al [12] reported that endoscopic DCR, when compared with external DCR, has a lower success rate, but

# REFERENCES

- 1- Caldwell GW. Two new operations for obstruction of nasal duct with preservation of canaliculi. Am J Ophthalmol 1893, 10:189.
- 2- Toti A Zumprincip, Zur deschte. Technique under dacryocystorhinostomie. Augenheilk.1910, 23 : 232-39 (after Sarwar MK and Jones NS, ENT News, 11:455-60).
- 3- West JM. A window resection of the nasal duct in cases of stenosis. Trans Am. Ophthalmol Soc. 1914,108:1172-76.
- 4- Metson R. Endoscopic revision dacryocystorhinostomy. Laryngoscope.1990; 100:1344-47
- 5- Metson R. Endoscopic surgery for lacrimal obstruction. Otolaryngol Head Neck Surg.1991; Apr;104(4): 473-9.
- 6- Massaro BM, Gonnering R, Harris G. Endonasal laser dacryocystorhinostomy. Arch. Ophthalmol 1990;108:1172-76.
- 7- Selig YK, Biesman BS, Rebeiz EE. Topical application of mitomycin-C in endoscopic dacryocystorhino-stomy. Am J Rhinol.2000; May-Jun;14(3):205-7.
- 8- weidenbecher M, Hosemann W, Buhr W. Endoscopic endonasal dacryocystorhinostomy: results in 56 patients. Ann Otol Rhinol Laryngol 1994;103:267.
- 9- Hartikainen J, Anttila J, Varpula M, Puukka P, Seppa H, Grenman R. Prospective randomized comparison of endonasal endoscopic dacryocystorhinostomy and external dacryocystorhinostomy. Laryngoscope.1998 Dec;108(12):1861-6
- 10- Cokkeser Y, Evereklioglu C, Er H. Comparative external versus endoscopic dacryocystorhinostomy: results in 115 patients (130 eyes). Otolaryngol Head Neck Surg 2000 Oct; 123(4): 488-91.
- 11-Dietrich C, Mewes T, Kuhnemund M, Hashemi B, Mann WJ, Amede. Long term follow-up of patients with microscopic endonasal dacryocystorhinostomy. Am J Rhinol.2003 Jan-Feb; 17(1):57-61
- 12-Zilelioglu G, Tekeli O, Ugurba SH, Akiner M, Akturk T, Anadolu Y. Results of endoscopic endonasal non-laser dacryocystorhinostomy. Doc Ophthalmol.2002 Jul;105(1):57-62.
- 13-Siegert R, Weerda H. Diaphanosopic localization of tear ducts in endonasal dacryocystorhinostomy. Laryngorhinotologie.1996 May;75(5):309-10.
- 14-May A, Fries U, Zubcov-Ivantscheff A, Luchtenberger M, Weber A. Endoillumination-guided intranasal microscopic dacryocystorhinostomy for difficult cases. ORL J Otorhinolaryngol Relat Spec.2002 Jan-Feb;64(1):11-15.
- 15-Metson R. Holmium : YAG endoscopic sinus surgery: a randomized, controlled study. Laryngoscope.1996. Jan; 106 (1Pt2, Suppl 77):1-18.
- 16-Onerci M. Dacryocystorhinostomy. Diagnosis and treatment of nasolacrimal canal obstruction. Rhinology. 2002 Jun; 40(2):49-65.
- 17-Gonnering RS, Lyon DB, Fisher JC. Endoscopic laser-assisted lacrimal surgery. Am J Ophthalmol.1991 Feb 15;111(2):152-7.
- 18-Hofmann T, Lackner A, Muellner K, Luxenberger W, Wolf G. Endolacrimal KTP laser-assisted dacrocystorhinostomy. Arch Otolaryngol Head Neck Surg 2003 Mar; 129(3):329-32.
- 19- Metson R, Woog JJ, Pulliafito CA. Holmium : YAG endonasal laser dacryocystorhinostomy. Laryngoscope. 1994 Mar; 104(3 Pt 1): 269-74.
- 20- Pearlman SJ, Michalos P, Leib ML, Moazed KT. Translacrimar transnasal laser-assisted dacryocystorhinostomy. Laryngoscope 1997 Oct;107(10):1362-5.
- 21-Cokkeser Y, Evereklioglu C, Tercan M, Hepsen IF. Hammer-chisel technique in endoscopic dacryocystorhinostomy. Ann Otol Rhinol Laryngol. 2003 May; 112(5): 444-9.
- 22-Whittet HB, Shun-Shin GA, Awdry P. Functional endoscopic transnasal dacryocystorhinostomy. Eye. 1993; 7(Pt 4) : 545-9.
- 23-Eloy P, Bertrand B, Martinez M, Hoebeke M, Watelet JB, Jamart J. Endoscopic dacryocystorhinostomy : indications, technique and results. Rhinology.1995 Dec;33(4):229-33.
- 24-Mantynen J, Yoshitsugu M, Rautiainen M. Results of dacryocystorhinostomy in 96 patients. Acta Otolaryngol Suppl. 1997; 529:187-9.
- 25-Unlu HH,Ozturk F, Mutlu C, Ilker SS, Tarhan S. Auris Nasus Larynx.2000 Jan;27(1):65-71.
- 26-Unlu HH, Toprak B, Aslan A, Guler C. Comparison of surgical outcomes in primary endoscopic dacryocystorhinostomy with and without silicone intubation. Ann Otol Rhinol Laryngol.2002 Aug; 111(8): 704-9.
- 27-Zilelioglu G, Ugurba SH, Anadolu Y, Akiner M, Akturk T. Adjunctive use of mitomycin C on endoscopic lacrimal surgery. Br J Ophthalmol.1998 Jan;82(1):63-6.