



# Anatomy Of The Larynx

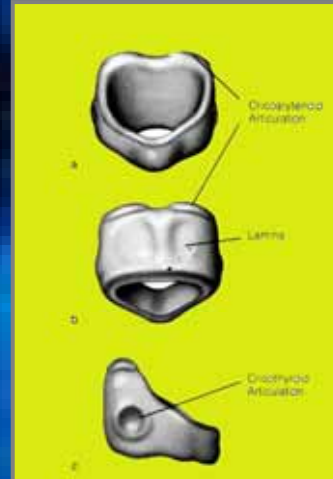
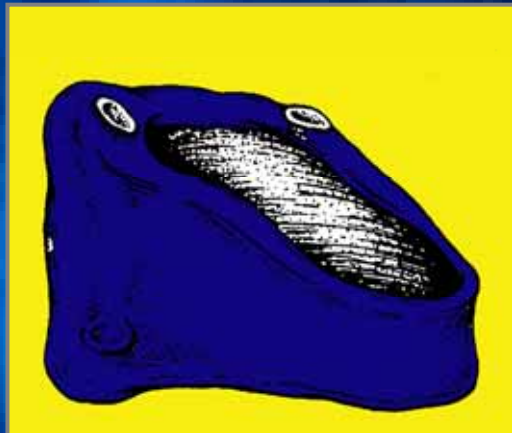
**Prof.M.Hesham**

Department of ORL-HNS  
Alexandria Faculty of Medicine

## Skeletal Framework

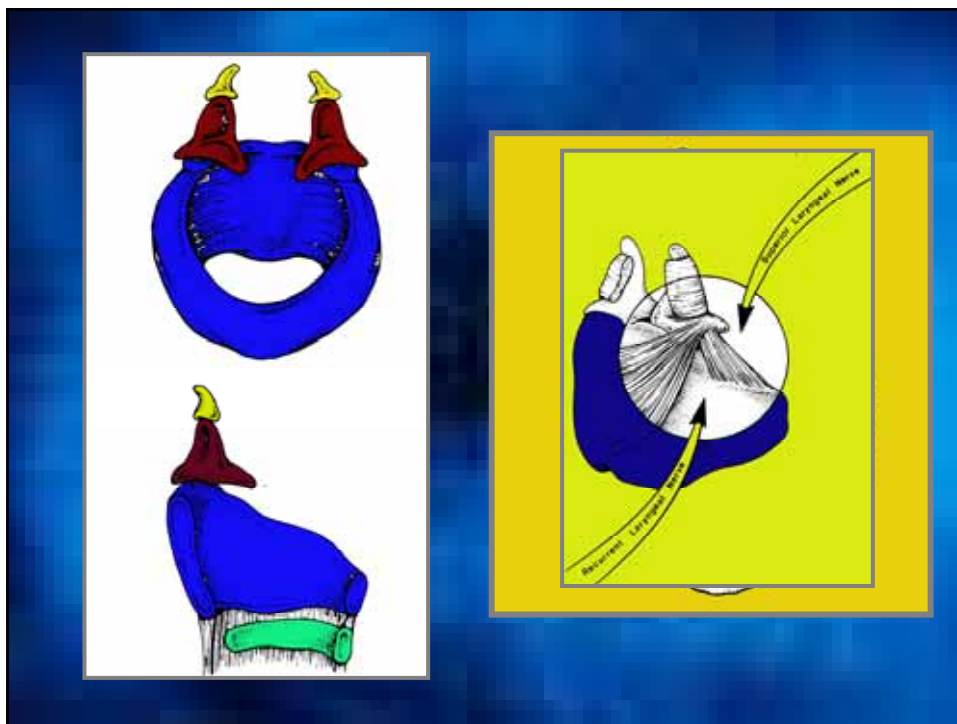
- Laryngeal cartilage
- Hyoid bone

### Circoid Cartilage

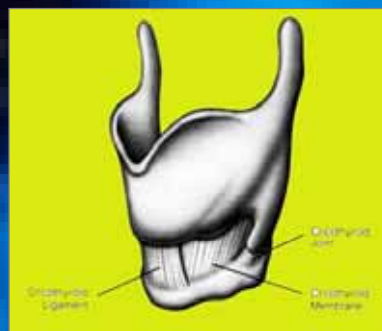
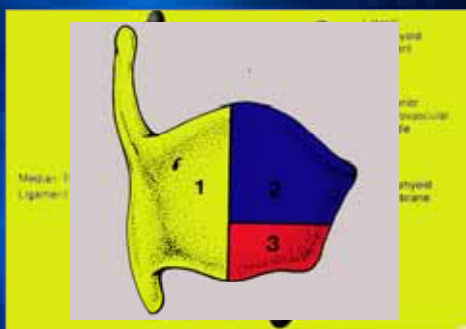


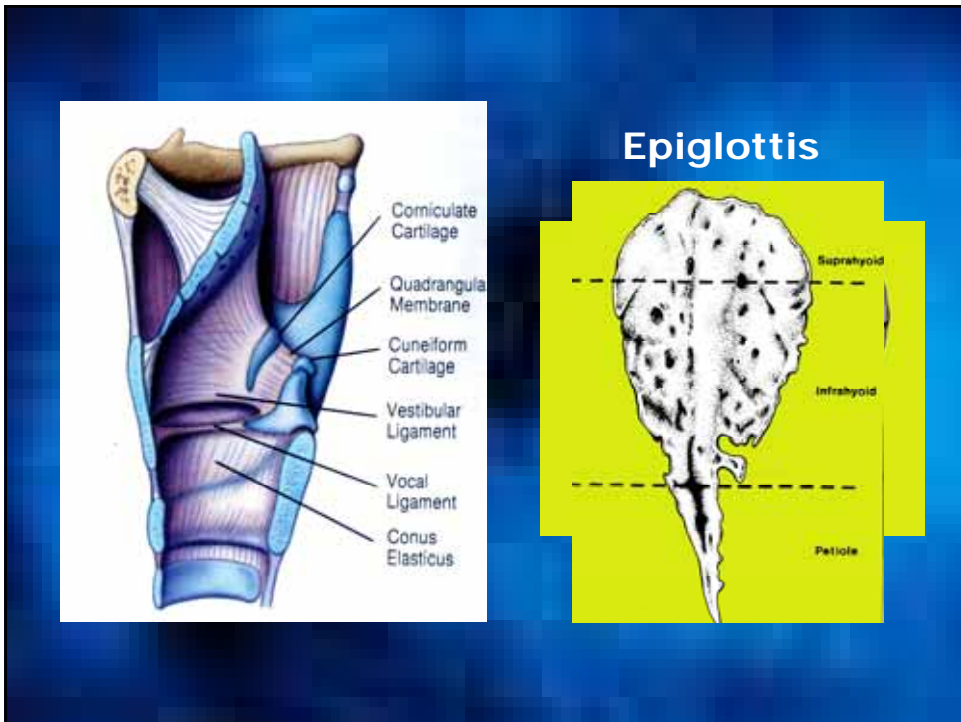
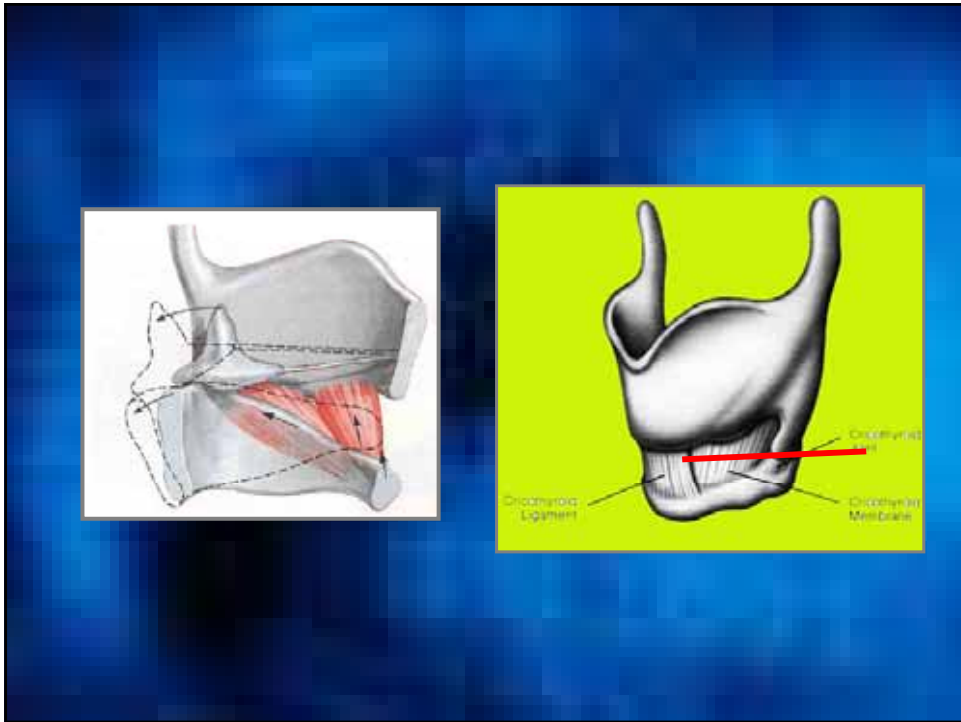
### Arytenoid Cartilage





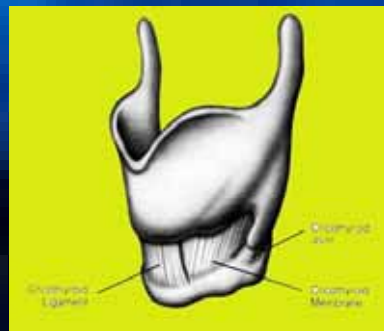
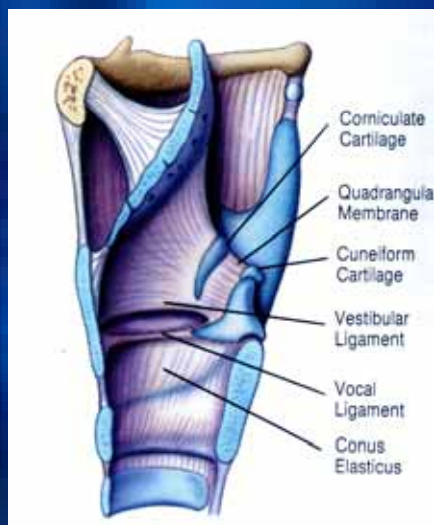### Thyroid Cartilage



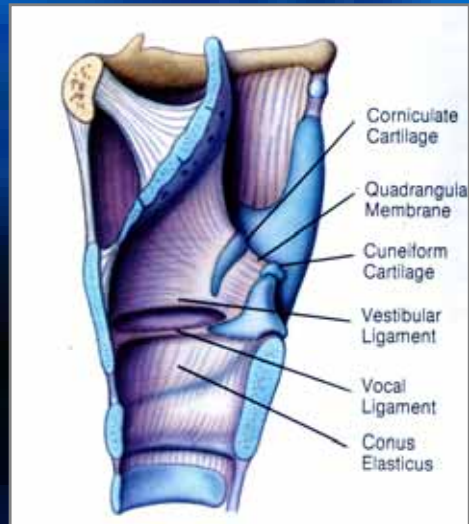

## Laryngeal ligaments and Membranes

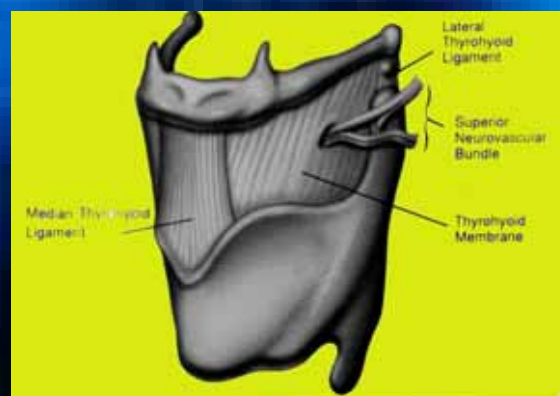
### Conus Elasticus



## Quadrangular membrane



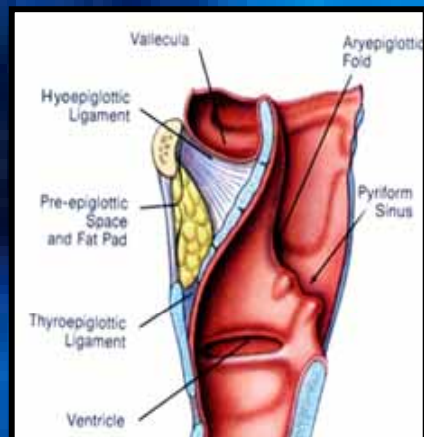
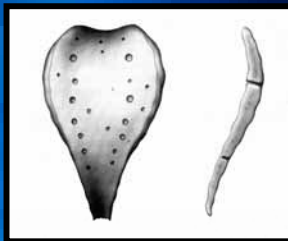
## Thyrohyoid Membrane

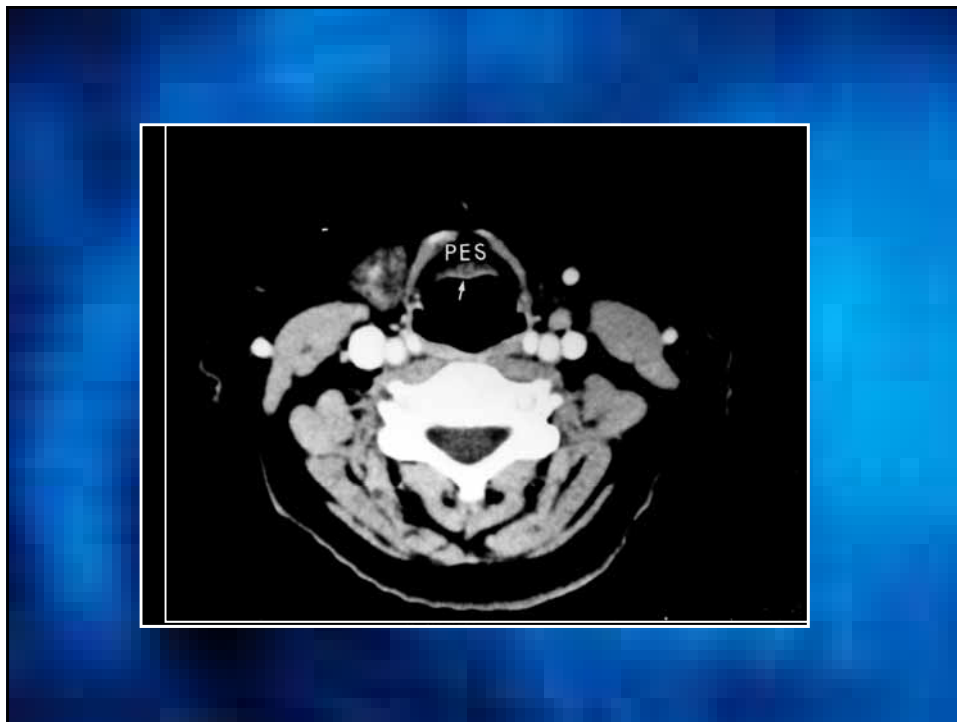


## Laryngeal Spaces

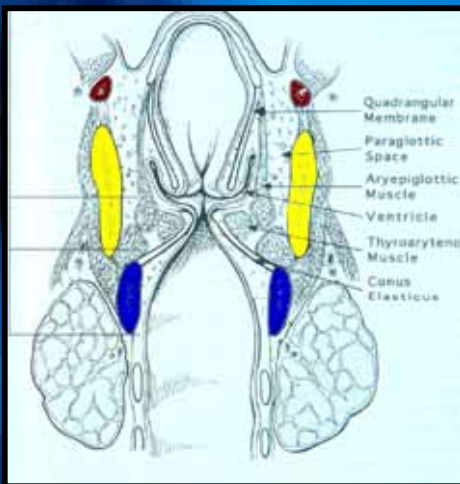
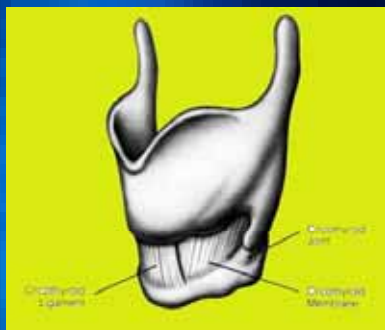
- Preepiglottic space
- Paraglottic space

### Preepiglottic space



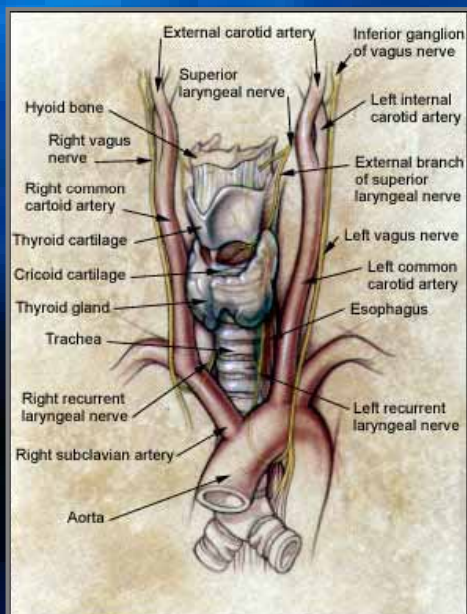
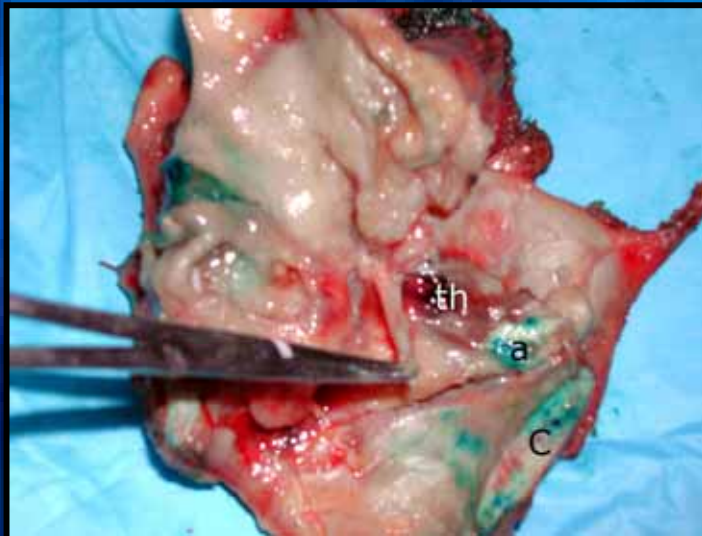


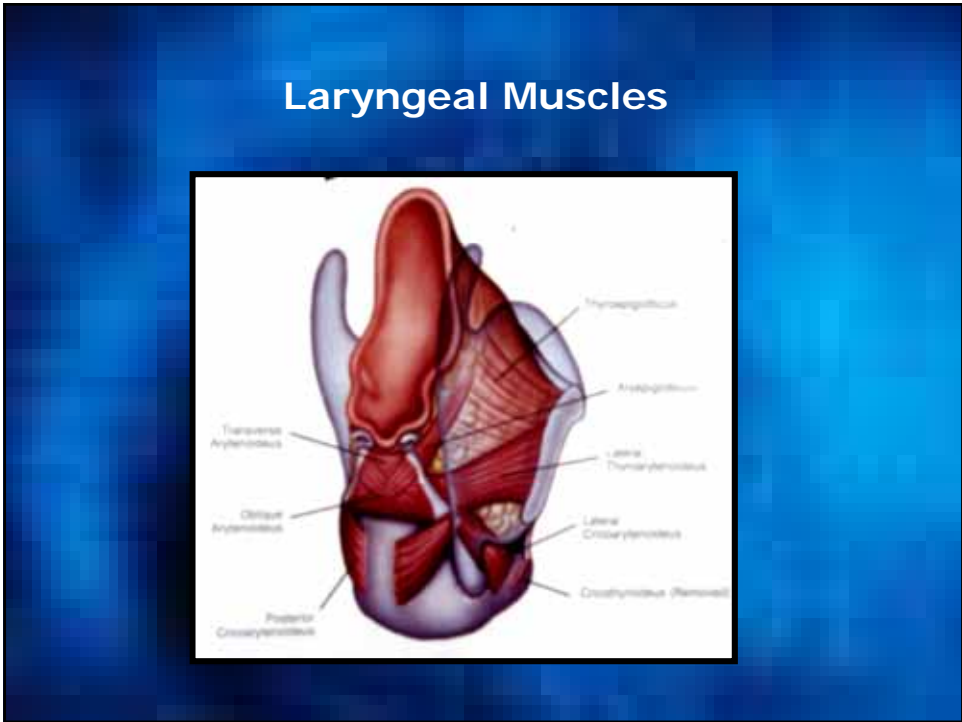
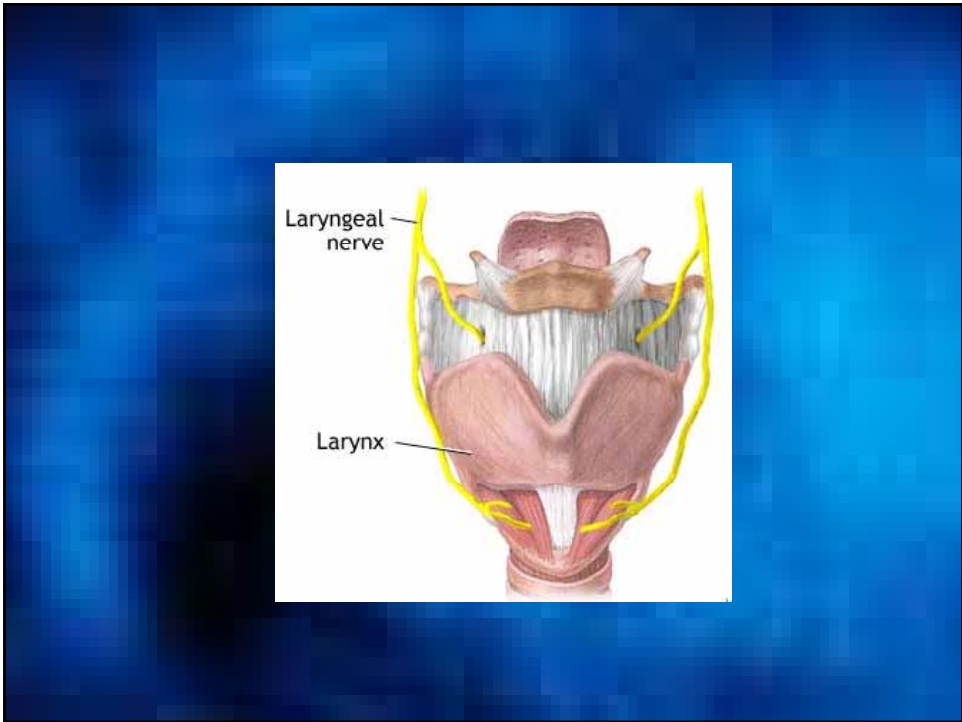
### Paraglottic space





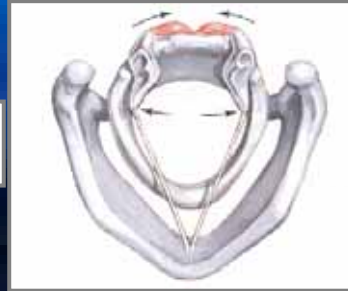
## Paraglottic space





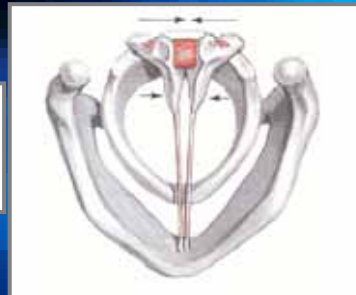### Posterior cricoarytenoid

- The only abductor muscle



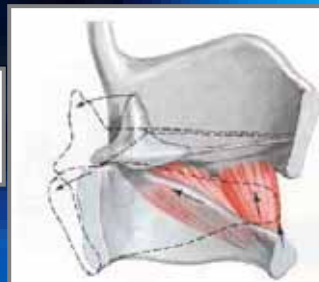
### Adductor muscles

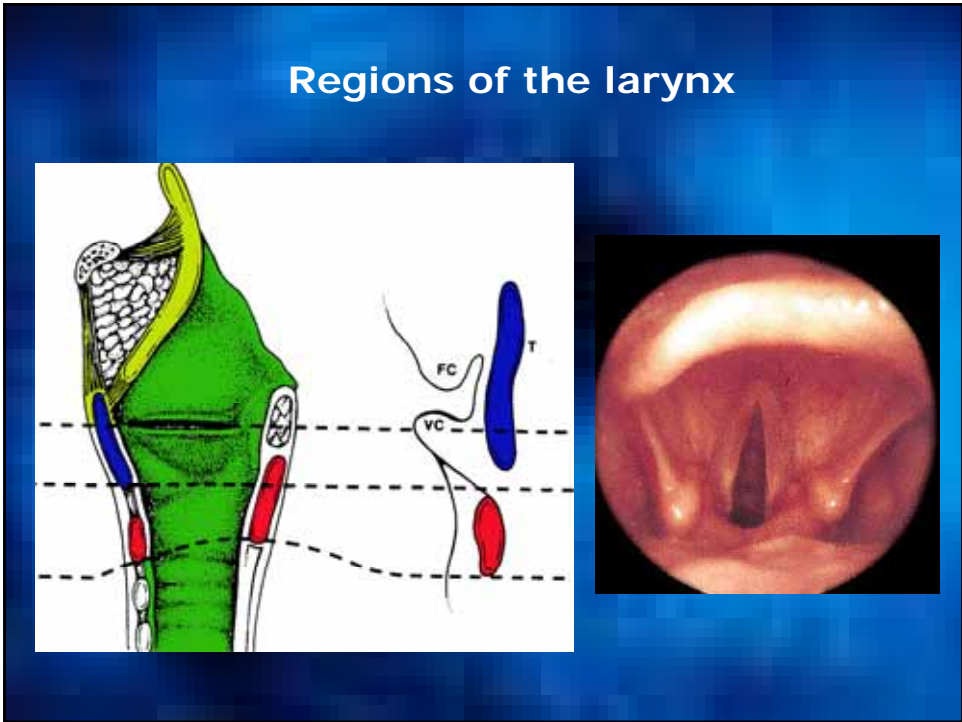
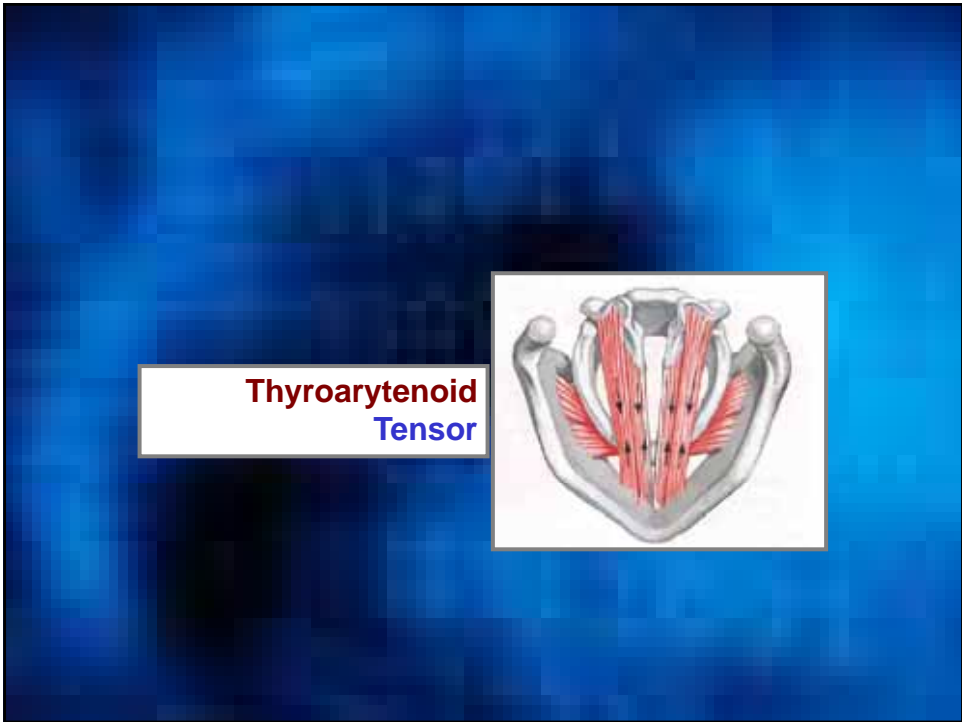
- Lateral cricoarytenoid
- Interarytenoid

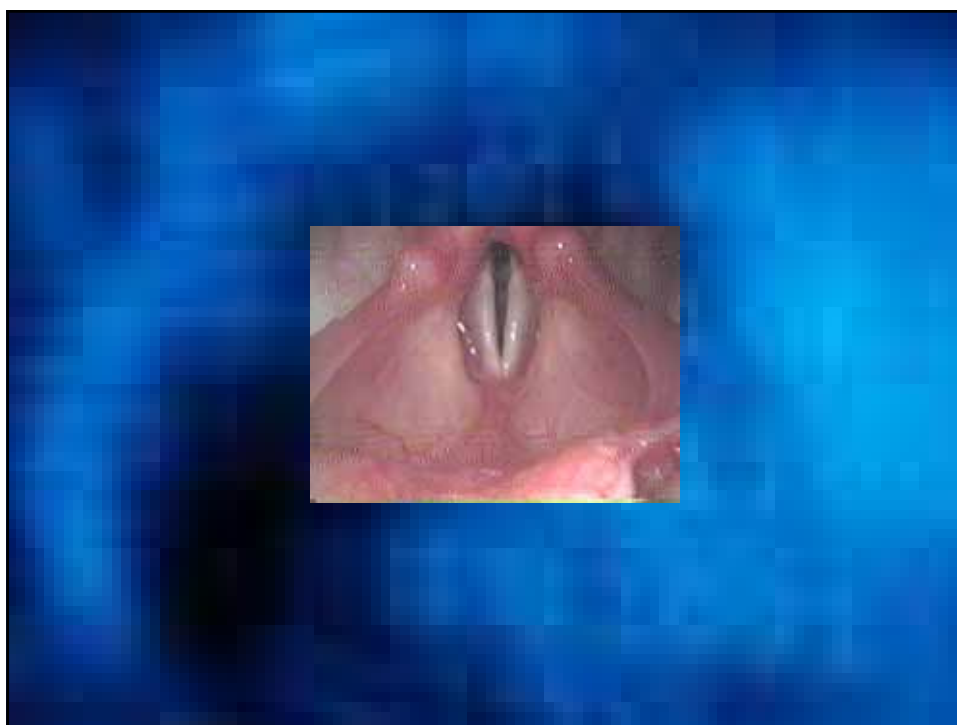
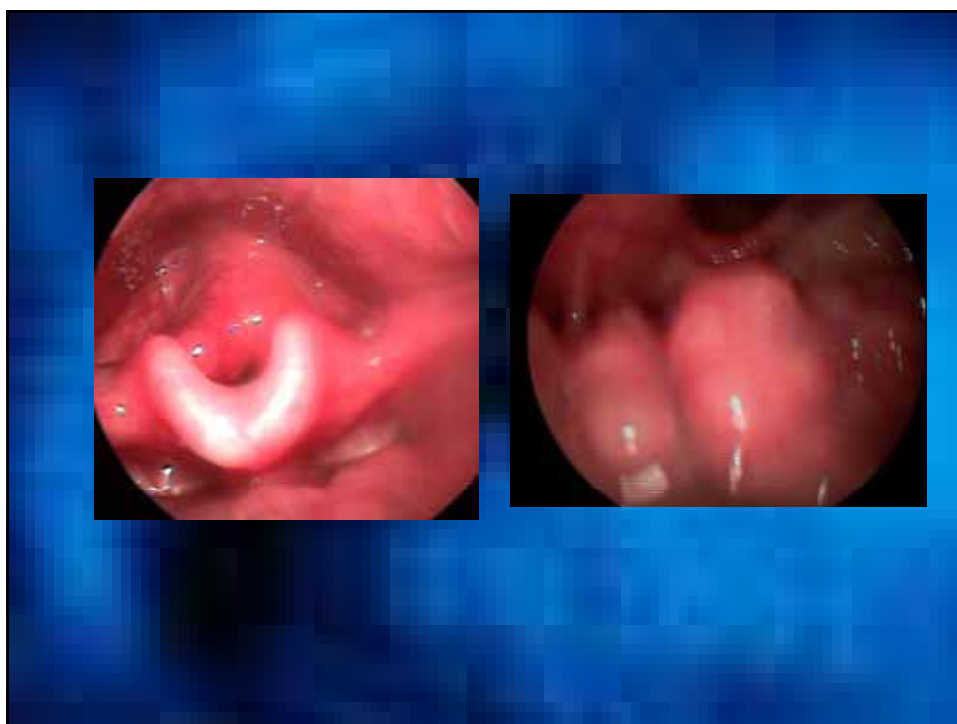

### Cricothyroid muscle

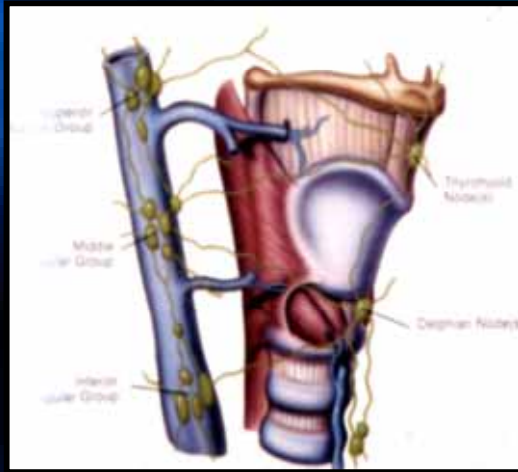
- Tensor
- Adductor !







## Lymphatic Drainage



**Thank You**