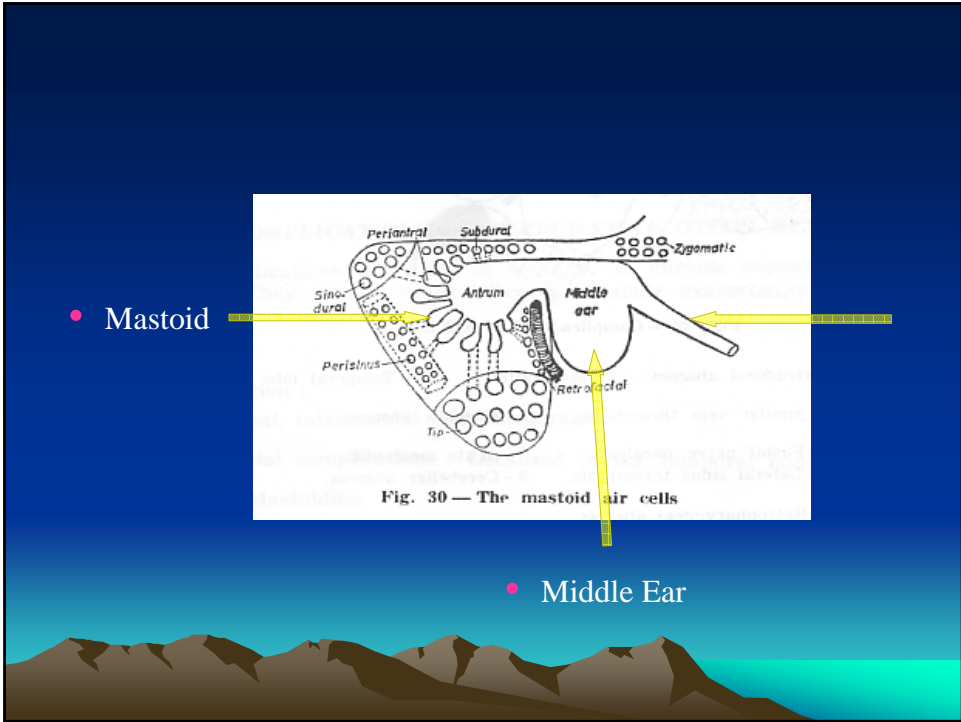
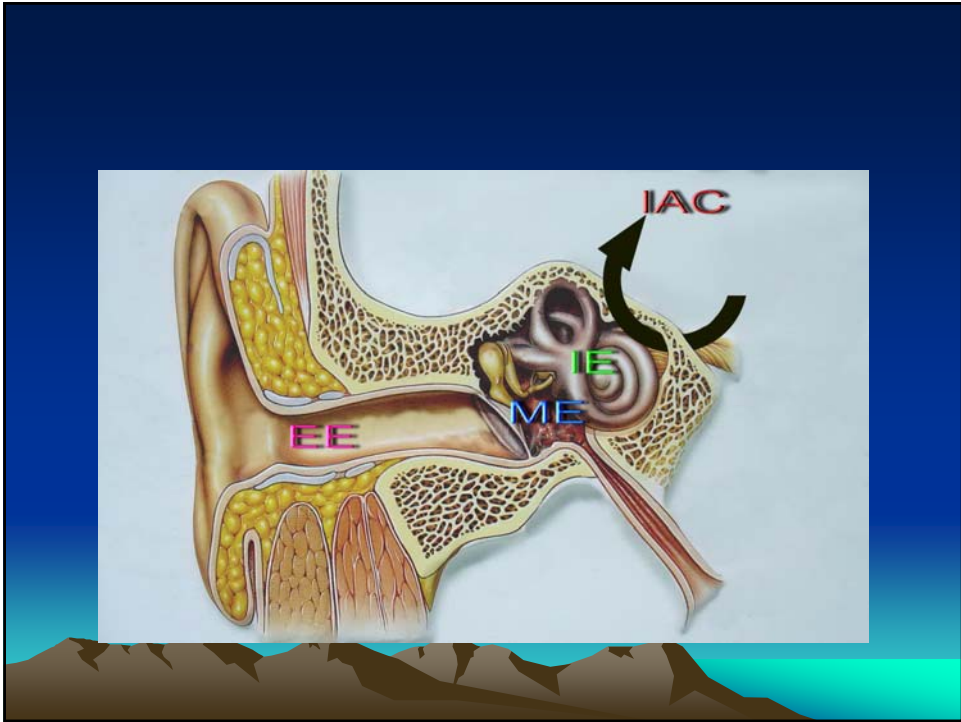


Otitis Media

Dr. Yasser Shewel

Definition

Inflammation of the mucoperiosteal lining of the middle ear cleft (Eustachian tube, tympanic cavity, mastoid antrum and mastoid air cell).



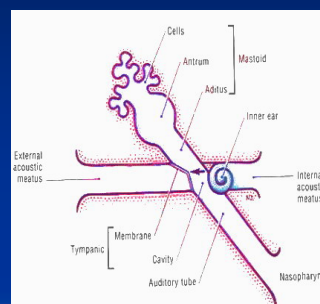
Classification

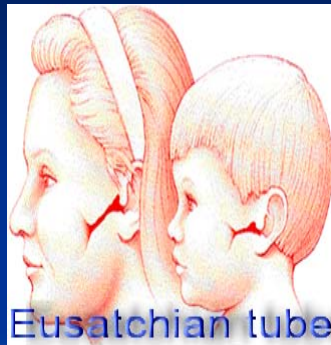- **Acute otitis media:**
 - Acute viral (non suppurative) otitis media.
 - Acute suppurative otitis media.
 - Acute Necrotizing otitis media.
- **Chronic otitis media:**
 - **Nonspecific:**
 - Chronic suppurative otitis media:
 - Chronic non-suppurative otitis media
 - ✓ Otitis media with effusion.
 - ✓ Chronic adhesive otitis media
 - ✓ Tympanosclerosis
 - ✓ Cholesterol granuloma
 - **Specific e.g. Tuberculous otitis media.**

Acute Suppurative Otitis Media

Definition

Acute inflammation of the mucoperiosteal lining of the middle ear cleft with **reversible** pathology





Incidence


- Acute otitis media is primarily a disease of children. Its peak incidence is during the first 6 years of life.



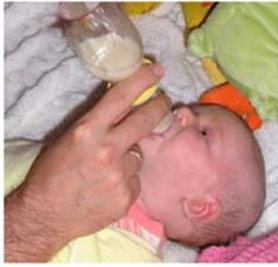- Several factors contribute to the prevalence of acute otitis media *media in early childhood. These include:*
 - Anatomical features of Eustachian tube :
 - The Eustachian tube is
 - shorter,
 - wider
 - and more horizontal than in adults
 - The orifices of the tube are surrounded by lymphoid tissues.
 - Frequent exposure to upper respiratory infections
 - Immature immune system

Predisposing factors

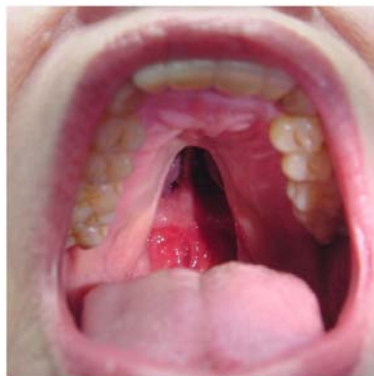- poor socioeconomic conditions
- Crowding
- Bottle feeding
- malnutrition,
- immunodeficiency
- Passive Smoking
- Pollution
- Mucociliary disorders



Nursery



Bottle Feeding



Cleft Palate

Bacteriology

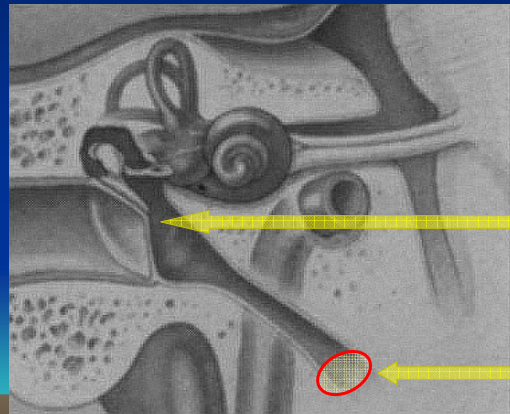
The common organisms include:

- Streptococcus pneumoniae,
- Moraxilla catarrhalis
- H. influenzae is more frequent during infancy and early childhood.
- Viral infection commonly precedes secondary bacterial invasion

Routes of infection

- Through the Eustachian tubes: This is the commonest route.
- Through a drum perforation.

Pathophysiology ET blockage



Pathology

The inflammatory process passes through continuous stages

- **Stage of tubal occlusion**.....> negative pressure in the middle ear
- **Stage of catarrhal inflammation**...> The hyperemia and transudation
- **Stage of suppuration**
- **Stage of Resolution**: unless complications occur

Clinical picture

Acute otitis media is frequently preceded by upper respiratory infection.

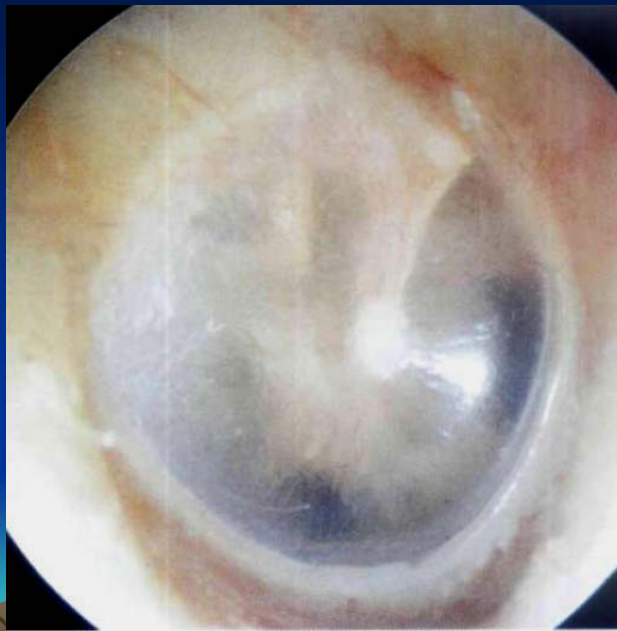- **Stage of tubal occlusion:**

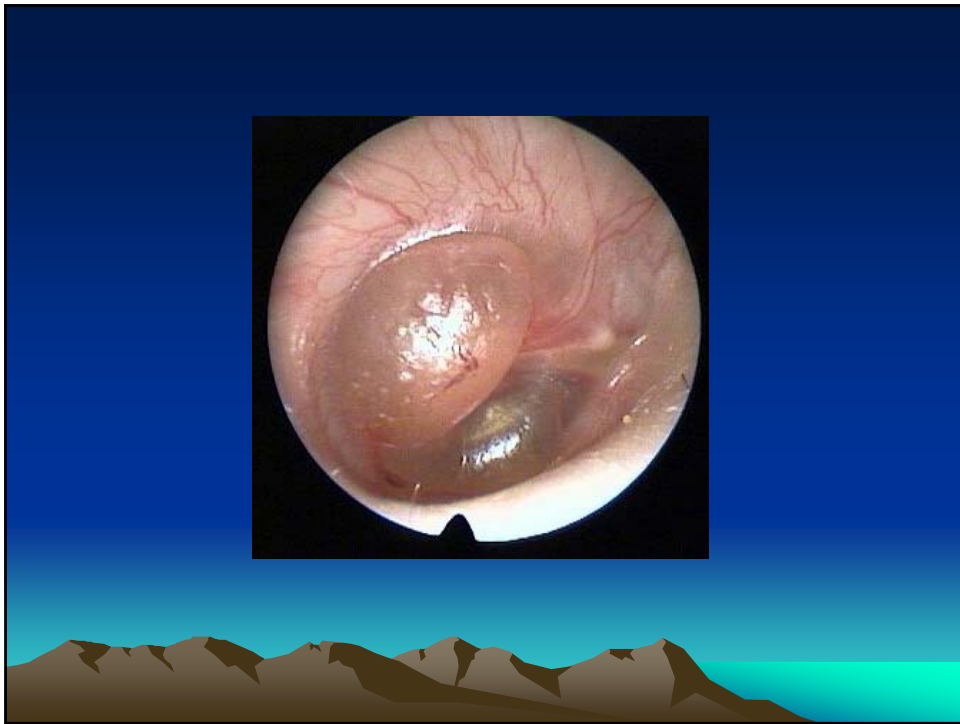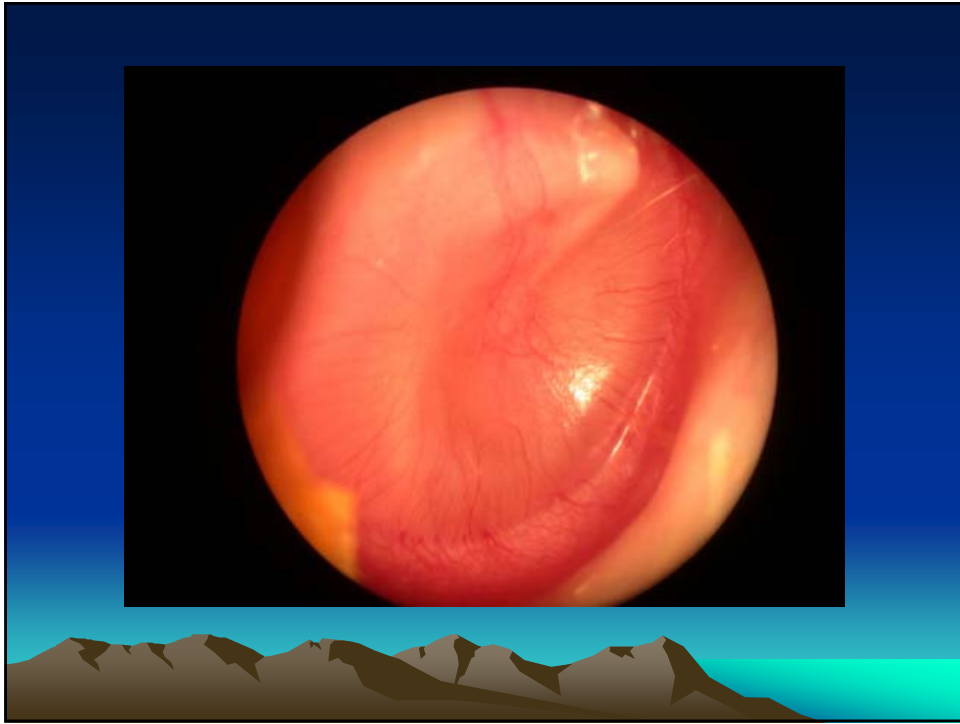- May be mild fever.
- Sense of fullness in the ear
- Earache.
- mild conductive hearing loss
- The tympanic membrane appears retracted, congested, and lusterless.

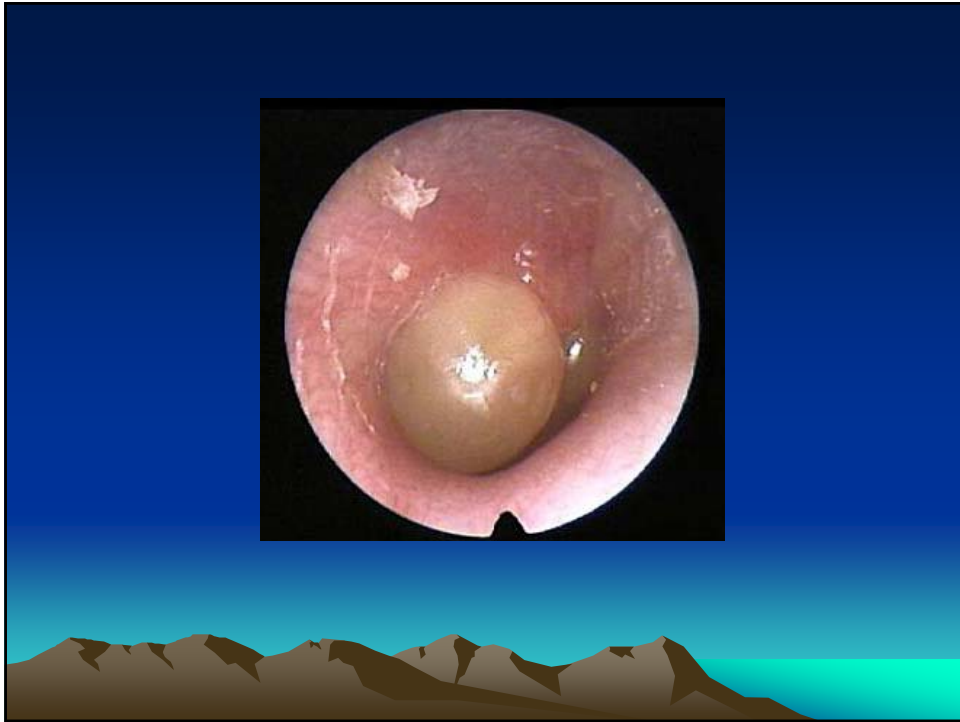- **Stage of acute catarrhal otitis media:**

- Fever
- Fullness
- Increasing ear ache.
- Mild conductive hearing loss
- The tympanic membrane appears retracted, congested (especially the pars flaccida) + signs of fluid behind the tympanic membrane

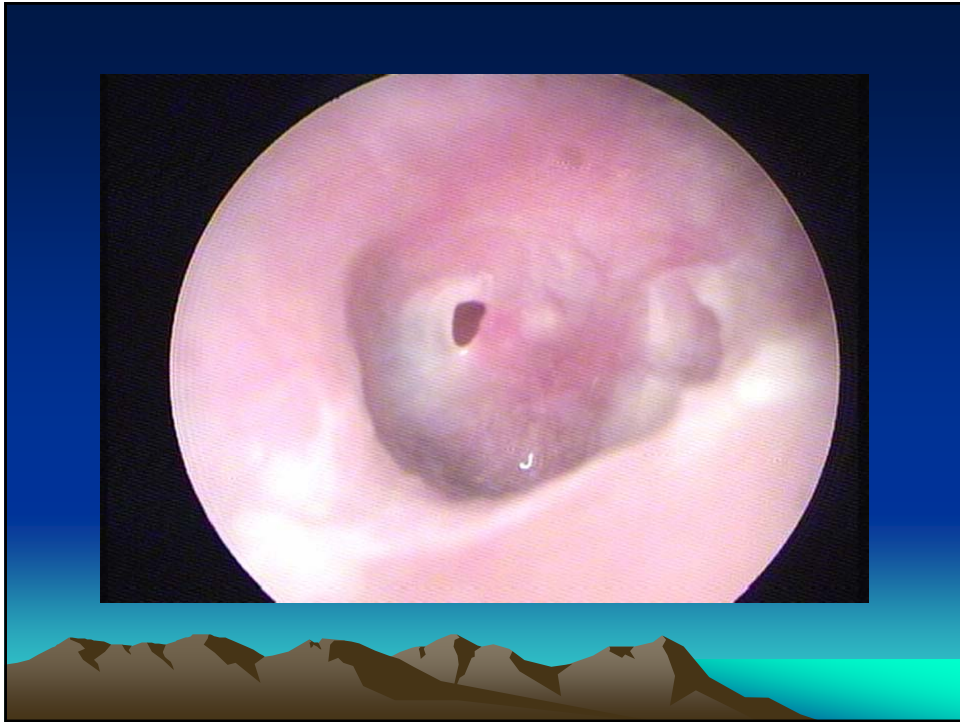- **Stage of acute suppurative otitis media (before rupture of tympanic membrane):**
 - High fever.
 - Severe throbbing pain.
 - CHL
 - The tympanic membrane
 - markedly congested,
 - bulging, first in the posterior half
 - Later on a yellowish spot appears indicating impending rupture of tympanic membrane
 - tenderness over the mastoid process (mastoidism). If it persists, **it indicates** bone involvement i.e.mastoiditis.







- **Stage of acute suppurative otitis media (after rupture of tympanic membrane):**
 - Rapid relief of pain, fever and CHL.
 - discharge
 - Small central perforation. The perforation is frequently located in the anteroinferior quadrant but may be present anywhere in the pars tensa. If the perforation is small the discharge may appear pulsating,



- **Stage of resolution:**
 - Resolution may occur with treatment
 - or after perforation of the drum membrane.

Differential diagnosis

- Other causes of otalgia
- Red tympanic membrane

Treatment:

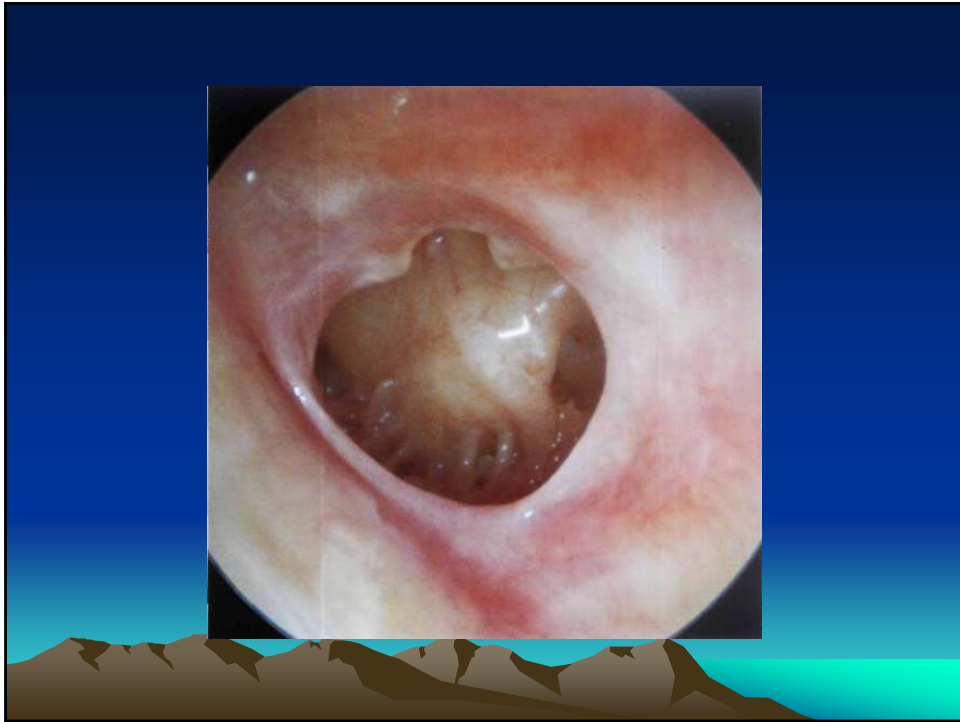- Before the perforation :
 - Antibiotic
 - decongestant
 - Antipyretic- analgesic preparations.
 - Myringotomy (when)
- After the perforation of tympanic membrane
 - Antibiotics (Culture and sensitivity of the discharge may be needed)
 - Antibiotic ear drops.
 - Decongestant
 - Frequent cleaning of the ear.
 - Myringotomy (when)

Acute necrotizing otitis media

A severe form of otitis media occurring in ill, toxic children suffering from measles and other exanthemata. It is caused by virulent hemolytic streptococci

characterized by necrosis and sloughing of tissues...>

- Large tympanic perforation....> predisposes CSOM
- foul smelling discharge
- Increase the risk of complications



Treatment:

- Frequent aural toilets (cleaning).
- Culture and sensitivity of the discharge.
- Systemic and local antibiotics.
- Treatment of sequels and complications e.g. tympanoplasty